



Effects of Uncultured Adipose Derived Stromal Vascular Fraction on Tendon Healing in Rabbits: A Histological and Immunohistochemical Study

Mehdi Behfar¹ DVM
Farshid Sarrafzadeh-Rezaei^{1*} DVSc
Rahim Hobbenaghi² PhD
Nowruz Delirezh³ PhD
Bahram Dalir-Naghadeh¹ DVSc

¹ Department of Clinical Sciences, Faculty of Veterinary Medicine,
Urmia University, Urmia, Iran

² Department of Pathobiology, Faculty of Veterinary Medicine,
Urmia University, Urmia, Iran

³ Department of Cellular and Molecular Biotechnology, Institute of Biotechnology,
Urmia University, Urmia, Iran

Abstract

Objective- To evaluate the potential effects of uncultured adipose derived stromal vascular fraction on tendon healing.

Design- Prospective descriptive study.

Animals- Twenty five adult male New Zealand white rabbits, weighing 2.5-3.0 kg were used. Five rabbits were used as donors of adipose tissue and the rest were divided into control and treatment groups.

Procedures- The injury model was unilateral complete tenotomy through the middle one third of deep digital flexor tendon. Immediately after suture repair, either fresh stromal vascular fraction from enzymatic digestion of adipose tissue or placebo was intratendinously injected at tendon stumps in treatments and controls, respectively. Immobilization with cast was continued for two weeks after surgery. Animals were sacrificed at three and eight weeks after surgery and tendons underwent histological and immunohistochemical evaluations.

Results- By histology, superior fibrillar organization and remodeling of neotendon were observed in response to the treatment at both time points. As the main finding of immunohistochemistry, treatment at the later time point resulted in significant increase in collagen I and decrease in collagen III expression compared to controls.

* Corresponding author:

Farshid Sarrafzadeh-Rezaei, DVM, DVSc

Department of Clinical Sciences, Faculty of Veterinary Medicine, Urmia University, Urmia, Iran,

E-mail: f.sarrafzadeh@urmia.ac.ir or fsrezaei@gmail.com

Conclusions and clinical Relevance- The present study showed that intratendinous injection of uncultured adipose derived stromal vascular fraction resulted in improved structural properties of tendon repairs and it could be an effective modality for treating tendon injury.

Key words- Adipose tissue, Stromal cell, Tendon, Histology, Immunohistochemistry.

Introduction

Injuries to tendons are of concern because of the limitations of tendon healing. When a tendon is injured, the resultant scar tissue is inferior to normal tendon and prone to re-injury.¹ Current therapies for tendon injuries include conservative and surgical treatments. Currently, a paradigm shift in treatment is occurring with the introduction of regenerative medicine. The use of progenitor or mesenchymal stromal cells (MSCs) for tendon injury has become increasingly popular. It has been demonstrated that bone marrow and adipose tissue contain progenitor cells^{2,3} capable of differentiating into tenocytes.^{4,5} Despite the promising results from several studies using MSCs, ex vivo culture of cells is an expensive, labor intense, and fairly lengthy process. Further, the properties of each expansion product appear to vary from individual to individual.⁶ Therefore, a more proliferative cell population, not only would overcome these limitations, but also provides the chance of performing single step procedure in clinical practice. One such candidate is stromal vascular fraction (SVF), a heterogeneous cell population derived from minimal manipulation of adipose tissue, which is prepared within 1-2 hours and could be used for direct injection of fresh cells without culturing.⁷ It has been reported that SVF consists of adipose derived MSCs, circulating blood cells, fibroblasts, pericytes, as well as endothelial progenitor cells.⁸ Time-consuming invasive protocols, which carry a risk of culture contamination and/or genetic modification with possible malignant transformation, are not necessary with this method. In addition, there is no need of using culture serum (including fetal calf serum), which may be associated with the transmission of disease and antibody formation.⁷

Previously, Nixon and colleagues used SVF on collagenase induced tendinitis in an equine model and reported that intratendinous injection of SVF resulted in improved tendon architecture in treatment group.⁹ As the most critical time for tendon healing evaluation is during the first weeks after intervention,¹⁰ their study was limited by the lack of information from structural evaluations in the early stages of repair. In the present study we investigated potential healing effects of immediate intratendinous injection of SVF following primary suture repair of surgically transected tendons at three and eight weeks after-surgery in rabbits.

Materials and Methods

Experimental Animals

All protocols were reviewed and approved by the authors' Institutional Ethics Committee before animal experimentation. Twenty five adult male New Zealand white rabbits, weighing 2.5-3.0 kg were used. During the study animals were housed individually in stainless steel cages (60×55×40 cm), under standard conditions and given food (commercial rabbit pellet) and water *ad libitum*. A group of five rabbits were used as donors of adipose tissue for preparation of SVF and the other twenty rabbits were divided randomly and equally into control and treatment groups each of ten animals.

Preparation of Stromal Vascular Fraction

Donor rabbits were anesthetized with ketamine hydrochloride (Ketaset, 40 mg/kg, Rotexmedica, Trittau, Germany) and xylazine hydrochloride (Rompun, 10 mg/kg, Alfasan, Woerden, The Netherlands), intramuscularly. Aseptically, 6 to 8 g of bilateral inguinal fat pads was obtained through midline suprapubic skin incision. After harvesting adipose tissue the animals were euthanized by anesthetic overdose of thiopental sodium (Nesdonal, 50 mg/kg, Biochemie, Kundl, Austria), intravenously. Stromal vascular fraction was isolated using a procedure modified from Zuk.¹¹ Briefly, adipose tissue was finely minced, washed with phosphate-buffered saline (PBS), and centrifuged at 1200 g for 2 min to remove erythrocytes and cellular debris. Samples were then digested in a water bath for 60 min at 37° C by 0.1% collagenase type II (C6885, Sigma-Aldrich, Saint Louis, MO, USA) in PBS. After digestion, collagenase was neutralized by adding an equal volume of DMEM (Dulbecco's Modified Eagle Medium, Sigma-Aldrich, Saint Louis, MO, USA). The digestate was centrifuged for 10 min at 1200 g to separate SVF from adipocytes, cellular debris and undigested tissue. After removal of the supernatant, the cell suspension was filtered through a sterile 100 µm nylon cell strainer (BD Falcon, Bedford, MA, USA) into a new tube and centrifuged again. The resulting pellet was re-suspended in PBS and freshly transferred to the operating room for transplantation procedure. The mean number of nucleated cells isolated per gram of adipose tissue was approximately $2 \pm 0.50 \times 10^6$. Cell viability was assessed by trypan blue exclusion assay which was higher than 95%.

Surgical Procedure

The model animals were anaesthetized using the same anesthetic protocol as used previously. One hind limb of each rabbit was randomly prepared for aseptic surgical procedure. Plantar skin was incised longitudinally and deep digital flexor tendon was exposed, subsequently. The injury model was a sharp complete transection through the midsubstance of the tendon. Then tendon stumps were sutured with 3-0 monofilament nylon (Ethilon, Ethicon, Inc., Somerville, NJ, USA) in modified Kessler pattern. Freshly isolated SVF (approximately 4×10^6 nucleated cells) in 0.2 ml PBS solution injected intratendinously at both tendon stumps and the repair site in treatment group. Controls underwent the identical procedures except that they just received the same volume of PBS. The skin was closed routinely and a below stifle cast was applied after operation and immobilization was continued for two weeks. No antibiotics were given to the animals neither in control nor in treatment groups. Half of rabbits in control and treatment groups were sacrificed at three and the rest at eight weeks after surgery as mentioned before.

Histological Evaluations

The harvested tendon was fixed by immersion in 10% neutral-buffered formalin. Subsequently, specimens were dehydrated and embedded in paraffin wax in order to prepare sections, according to the longitudinal axis, at a thickness of 5 µm from the region of the tenotomy site and the surrounding native tendon. Sections were stained with Haematoxylin & Eosin (H&E) and were evaluated under a light microscope, equipped with a vernier scale to the nearest 0.1 mm, by the following criteria:

Histological examination of repairs included assessment of areas including longitudinally oriented collagen fibers. In this regard, total area of neotendon between the severed ends of

tendons was measured at $40 \times$ magnification and the area consisting longitudinal pattern of collagen fibers was calculated. The ratio of these values was then obtained and defined as the percentage of fibrillar linearity for each tendon. The width of the widest part of neotendon including fibers following the direction of those in native tendon was measured at $40 \times$ magnification in both tendon-neotendon junctions and the ratio of their mean to the mean width of junctions was defined as the percentage of fibrillar continuity for each specimen. To examine the rate of angiogenesis within the neotendon and newly formed epitenon, the number of blood capillaries was counted at $100 \times$ magnification. For this evaluation, six randomly selected fields were examined per each tendon sample. The number of capillaries was recorded and results were reported as the mean value for the entire specimen. The thickness of the epitenon was measured at $100 \times$ magnification in three randomly selected points of epitenon on both sides of neotendon and the numbers were averaged for each specimen.

Immunohistochemical Evaluations

To evaluate the type of collagen synthesized in neotendon the following antibodies were used in sections: mouse monoclonal antibody to collagen I (Col I) (ab6308, Abcam, Ltd., Cambridge, UK) and mouse monoclonal antibody to collagen III (Col III) (ab6310, Abcam, Ltd., Cambridge, UK). The expression of Col I and III was measured by immunohistochemical staining according to the instructions of the immunohistochemistry kit.

Immunohistochemical evaluation was made for intensity and localization of the immunostaining of Col I and III at the repair site of specimens, assessed at $100 \times$ magnification. A score of 0 (absence of antigen expression), 1 (weak and spotted antigen expression), 2 (weak but diffuse antigen expression throughout the entire repair site), and 3 (diffuse and strong antigen expression) was assigned to the semi quantitative evaluation of the immunohistochemical reaction to each antigen employed.

Statistical Analysis

Statistical analyses of quantitative data were carried out using PASW Statistics (Release 18, SPSS Inc., Chicago, Illinois, USA). The residuals were tested for normality by Shapiro-Wilk's test and normality plots (histograms and quantile quantile plots) and for homogeneity of variation by Levene's test and examining residual plot. Normality and/or homogeneity of variance assumptions for other variables were not satisfied and prior to statistical analysis these variables were logarithmically transformed to fulfill model assumptions. Statistical analysis of data was assessed using one-way analysis of variance (ANOVA). Multiple comparisons were made by using post-hoc tests (Tukey's method) to find which groups were significantly different from each other. Data are presented as mean \pm standard deviation. The level of significance was set at $p < 0.05$. The results are presented as mean and standard deviation (mean \pm SD). Comparison of immunohistochemical scores across groups was performed with Kruskal-Wallis One Way Analysis of Variance on Ranks followed by Mann-Whitney U-test for pairwise comparison. Bonferoni corrections were made to maintain the familywise alpha level at 0.05 for multiple comparison. The results are expressed as median and interquartile range (IQR 25 and IQR 75).

Results

At three and eight weeks after surgery, the tenotomy site had healed well in all animals. No evidence of faulty union and local or systemic complications was observed. Dehiscence of the suture with gap formation between the tendon stumps was not seen in any of the tendons. In addition, there was no noticeable adhesion formation between the tendons and its surrounding tissues in all groups. The histological and immunohistochemical results of study are presented in Tables 1 and 2, respectively.

Table 1. Results of histological studies (mean±SD) of repairs at three and eight weeks after surgery.

| | No. | Percentage of fibrillar linearity | Percentage of fibrillar continuity | Number of capillaries in neotendon | Number of capillaries in epitenon | Epitenon thickness (µm) |
|-------------------|-----|-----------------------------------|------------------------------------|------------------------------------|-----------------------------------|--------------------------|
| Control 3 weeks | 5 | 15.42±4.76 ^a | 24.49±3.97 ^a | 28.08±0.32 ^a | 9.32±1.24 ^a | 42.24±11.93 ^a |
| Treatment 3 weeks | 5 | 30.87±7.8 ^{bd} | 52.42±7.10 ^{bd} | 47.79±12.69 ^b | 19.26±4.98 ^b | 64.99±6.85 ^b |
| Control 8 weeks | 5 | 27.99±5.79 ^{bc} | 46.99±4.13 ^{bc} | 25.73±7.56 ^a | 15.13±1.97 ^{ac} | 32.06±4.70 ^{bc} |
| Treatment 8 weeks | 5 | 46.45±6.39 ^d | 62.91±3.98 ^d | 13.80±4.00 ^c | 10.19±1.30 ^c | 29.46±2.20 ^a |

^{abc} Values with different symbol in each column are significantly different ($p < 0.05$).

Table 2. Results of immunohistochemical evaluation [median and interquartile range (25–75%)] of collagen III and I expression in repairs at three and eight weeks after surgery.

| | Col III expression | Col I expression |
|-------------------|------------------------------------|-----------------------------------|
| Control 3 weeks | 1.000 (1.000-2.250) ^{abc} | 0.000 (0.000-1.000) ^{ab} |
| Treatment 3 weeks | 3.000 (2.750-3.000) ^a | 1.000 (0.750-1.250) ^{ab} |
| Control 8 weeks | 1.000 (0.750-1.250) ^{bc} | 1.000 (0.750-2.000) ^b |
| Treatment 8 weeks | 0.000 (0.000-1.250) ^c | 3.000 (2.000-3.000) ^c |

^{abc} Values with different symbol in each column are significantly different ($p < 0.05$).

Histological analysis showed that SVF-treated tendons exhibited significantly improved organization of neotendon characterized by parallel and linear orientation of collagen bundles (Fig. 1). Furthermore, superior fibrillar continuity was observed in treatments over controls at both time points ($p < 0.05$ for both comparisons). At third week, the number of blood capillaries of neotendon and epitenon in treatments significantly increased over controls ($p < 0.05$). By contrast, at eighth week, a significant decrease was detected when treatments were compared to their controls ($p < 0.05$) (Fig. 2). Epitenon thickness was also significantly increased in treatment group at the earlier time point ($p < 0.05$). At the later time, no significant changes were observed between the groups ($p > 0.05$).

According to the immunohistochemistry-based findings, the increase in expression of Col I and III observed in SVF-treated tendons at third week was not statistically significant ($p > 0.05$) (Fig. 3A versus 3B and 4A versus 4B).

In addition, at eighth week, decreased expression of Col III in treatments was not significant compared to their controls ($p > 0.05$) (Fig. 3C versus 3D). Furthermore, increased expression of Col I was statistically significant in treatment groups over controls ($p < 0.05$) (Fig. 4C versus 4D).

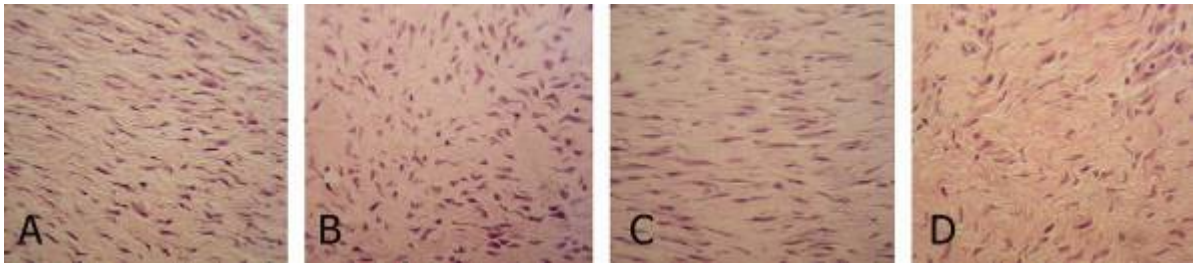


Figure 1. Three weeks after surgery, longitudinal arrangement of collagen fibers was improved in response to intratendinous injection of SVF in treatments (A) compared to controls (B). After 8 weeks, fibrillar linearity was also significantly increased in treatments as seen in (C) over controls (D). H&E \times 400.

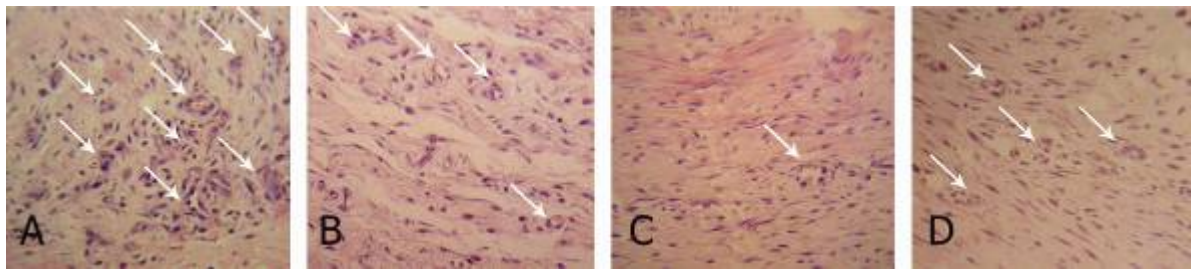


Figure 2. Arrows indicate blood capillaries in neotendon. At three weeks significant increase in the number of capillaries was found in treatment group (A) compared to controls (B). By contrast, at the eighth week, the number of capillaries was significantly decreased as a result of superior remodeling in SVF-treated tendons (C) over placebo received group (D). H&E \times 400.




Figure 3. At third week after surgery, there were no differences in collagen type III expression between treatments (A) and controls (B). The decrease rate of collagen type III at eight weeks was also showed no statistical differences between groups (C versus D). DAB brown \times 100.

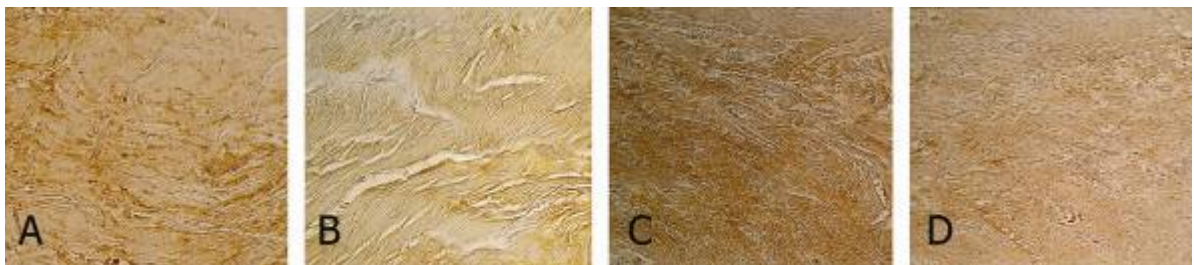


Figure 4. Increased expression of collagen type I in treatments (A) at third week was not statistically significant compared to controls (B). However, after eight weeks, there was a significant increase in localization and staining of collagen type I in SVF-treated tendon (C) over controls (D). DAB brown \times 100.

Time course analysis of results revealed that, increase in fibrillar linearity and continuity of neotendon followed an upward trend from third to eighth week. Interestingly, when comparing SVF-treated repairs at third week to controls at eighth week, no significant differences were found in terms of these two characteristics ($p > 0.05$). The number of blood capillaries at the eighth week repairs either in control or treatment groups were lower than those in their synonymous group at third week. The trend of hypovascularization in SVF-treated tendons was statistically significant ($p < 0.05$). This trend was also applicable for the rate of angiogenesis in epitenon, except for the significant hypervascularization in controls at the later time point ($p < 0.05$). Epitenon thickness followed a downward trend from third to eighth week within both groups of study. The trend of decrease in SVF-treated tendons was statistically significant ($p < 0.05$).

There were also some time-dependant changes in immunohistochemical results as follow:

No statistically significant difference was observed comparing the expression of Col I between the controls at third and eighth weeks ($p > 0.05$). However similar comparison showed a significant decrease in Col III expression ($p < 0.05$). Comparisons of the expression of Col I and Col III between treatment groups from third to eighth week, revealed a significant increase and decrease, respectively ($p < 0.05$ for both comparisons). The most remarkable finding was that no significant change was detected in terms of Col I expression between the third week's treatments and the eighth week's controls. Also, there was a significant decrease in expression of Col III at third week's treatment in comparison with eighth week's controls ($p < 0.05$ for both comparisons).

Discussion

The present results provide evidence that superior tendon regeneration can be achieved with intratendinous injection of adipose derived SVF compared to placebo in a rabbit model of experimentally transected flexor tendons. For example, advanced longitudinal organization of collagen fibers, fibrillar continuity and increased collagen type I expression observed in SVF-treated tendons over controls at both time points, directly indicates the beneficial effects of the treatment. However, there are other encouraging results requiring some additional explanations to help address the beneficial effects of using SVF in this study.

Few days after injury, inflammation in tendon subsides and fibroblast proliferation and biosynthesis of extracellular matrix and collagen (mostly type III) begin at around day 5. These new collagen fibrils scatter in the extracellular matrix and start to aggregate into organized bundles by day 21. Decrease in Col III contents and increase in Col I synthesis are main characteristics of remodeling phase of tendon healing which begins at 6–8 weeks after injury. Although Col III fibers are immature, weak and arranged haphazardly (compared to Col I fibers), they have implications for the stability of repaired tissue.¹² On the other hand, high expression of Col I and longitudinal organization of the fibers seem to be essential to achieve the tensile strength and faster healing of tendons.^{13,14} In fact, early rises in Col I content in response to treatment would provide the benefit of early increase in wound strength during the time in which the tendon is exposed to the potentials for re-injury.¹⁵ In this regard, our results from immunohistochemical evaluations of repairs support the use of SVF for tendon repair, as it briefly resulted in significant increase of Col I contents and faster decrease of Col III at eighth week.

Currently, both intrinsic and extrinsic mechanisms are believed to contribute to the tendon healing process. Tenocytes within the tendon and epitenon play an important role in the intrinsic mechanism, while in the extrinsic mechanism, inflammatory cells and fibroblasts from the overlying sheath and periphery are the main participants. Although synovial sheath cells move into the tendon core soon after tendon injury, there is a time lag in the initiation of intrinsic healing. It is therefore considered that if an intrinsic response could be stimulated at the early stage of tendon healing, the outcome of tendon repair would be preferable with regard to fewer complications such as peritendinous adhesion.¹⁰ In addition; the intrinsic mechanism is responsible for the reorganization of the collagen fibers and maintenance of fibrillar continuity.¹⁶ This concept of tendon healing helps reduce any possible adhesion to the surrounding tissue as well which provides better biomechanics by preserving normal gliding mechanism.¹⁷ In the present study, epitenon thickness was increased at the earlier time point, mostly in treatment group and then a reduction in thickness was found at the eighth week. This could be explained by the possible influence of the treatment on the epitenon, which might have a stimulatory effect on early proliferation and migration of epitenon cells to quickly bridge the tendon ends and afterward, by maturation, epitenon underwent regression to near its normal thickness.

Needless to mention the important role of fibroblasts as the major producer of collagen¹⁸ in tendon healing, previous studies reported that MSCs have the potentials to differentiate into tenocytes *in vitro* and *in vivo*.^{4,5,19-21} We assumed that fibroblasts (directly and immediately) and MSCs (indirectly and with delay) under the influences of growth factors included in SVF²² may have active roles to play in repair of tendon via intrinsic mechanism.

Angiogenesis is regarded as an important component of tendon healing, because blood circulation not only increases the oxygen content and significantly reduces the concentration of carbon dioxide in the tissue which may stimulate the healing process, but also it delivers nutrients and inflammatory cells to the wound site.²³ Our results concerning angiogenesis of neotendon and epitenon indicating increased vascular density in treatments over controls at third week and remarkable decrease at the eighth week, are consistent with the normal process of wound healing, as it says angiogenesis is initiated during the second week²³ and during the third phase of healing (i.e., maturation) vascular density decreases to near normal level.²⁴ However, there is an abnormal finding indicating increased number of blood capillaries in epitenon in the eighth week controls. This could be explained by two possibilities; the first hypothesis is that it may take more than three weeks to find the highest number of epitenon blood capillaries in natural process of healing. Therefore, by three weeks the number of epitenon capillaries in control group has not reached its peak level. By contrast, the higher level of vascularity observed in third week's treatments may be due to acceleratory effects of the treatment. Alternatively, supposing that natural reduction of epitenon vascularity may occur later than eight weeks; therefore, decreased number of capillaries observed in eighth week's treatment group may be under the influence of acceleratory effects of the treatment again.

The idea regarding accelerated healing in response to the treatment was inferred from the time course analysis of the histological and immunohistochemical results in which, although insignificant, increase in fibrillar linearity, continuity, and Col I expression were found when treatments at third week were compared to the controls at eighth week.

The value of bone marrow derived mesenchymal stromal cells (BMSCs) in the treatment of lesions in joint, skeletal and cardiac muscle, and other mesenchymal tissues has already been

demonstrated.²⁵⁻²⁸ This also applies to tendon injuries and was described in previous studies.²⁹⁻³³ However, the use of this technique requires a fairly sophisticated cell culture laboratory and highly qualified personnel, both of which are often not accessible to clinicians and/or are cost-prohibitive for all patients. In addition, at least 3-4 weeks elapse between bone marrow collection and the time of MSCs transplantation into the lesion, a delay that may have a negative impact on the quality and speed of tissue healing.³⁴ Furthermore, there are some reports that extensive in-vitro expansion seems to affect both the replication potential of BMSCs and their differentiation capacity.^{35,36} The adipose tissue is an alternative source for adult MSCs with multilineage differentiation capabilities. It has the advantage of being easily accessible and obtainable in large quantities, under local anesthesia, with minimal morbidity and discomfort.³ Uysal and Mizuno successfully used expanded adipose derived stromal cells in treatment of an experimental tendon injury and promising results were observed. However, like bone marrow, the limitations of cell expansion also apply to adipose tissue.³⁷ Previously, Zuk and colleagues reported that there is a significant fraction of cells with multilineage capacity which can be obtained quickly from minimal manipulation of adipose tissue. The putative multipotentiality of these cells and ease of procurement may make these cells an excellent choice for many cell-based tissue engineering strategies.³ In this regard, Nixon used SVF in treatment of a collagenase induced tendinitis in horses and encouraging results were found.⁹ The separation of SVF from adipose tissue makes it possible to obtain a large number of MSCs in a short period of time and by employing an uncomplicated technique without the need for cell culture.

Once injected into the tenotomy site, the ability of MSCs included in SVF to immediately clone and differentiate into tendon tissue helps to avoid the significant time delay in therapy associated with the use of cultured MSCs from either bone marrow or adipose tissue and thus may offer the advantage of a more rapid tissue healing and a sooner return of tendon to its functional level.

In conclusion, the present study showed that intratendinous injection of uncultured adipose derived stromal vascular fraction resulted in improved structural properties of tendon repairs and it could be an effective modality for treating tendon injury. Both low cost and easy to prepare properties of SVF may render it very useful in the clinical setting in future.

References

1. Muratore R, Akabas T, Muratore IB. High-intensity focused ultrasound ablation of ex vivo bovine Achilles tendon. *Ultrasound Med Biol* 2008;34:2043-2050.
2. Devine SM, Bartholomew AM, Mahmud N, et al. Mesenchymal stem cells are capable of homing to the bone marrow of non-human primates following systemic infusion. *Exp Hematol* 2001;29:244-255.
3. Zuk PA, Zhu M, Mizuno H, et al. Multilineage cells from human adipose tissue: implications for cell-based therapies. *Tissue Eng* 2001;7:211-228.
4. Wang QW, Chen ZL, Piao YJ. Mesenchymal stem cells differentiate into tenocytes by bone morphogenetic protein (BMP) 12 gene transfer. *J Biosci Bioeng* 2005;100:418-422.
5. Uysal AC, Mizuno H. Differentiation of adipose-derived stem cells for tendon repair. *Methods Mol Biol* 2011;702:443-451.

6. Fibbe WE, Lazarus HM. Mesenchymal stem cells and hematopoietic stem cell Transplantation. In: Atkinson K, eds. *Clinical bone marrow and blood stem cell transplantation*. 3rd ed. New York: Cambridge University Press, 2004;64-75.
7. Reinders ME, Rabelink TJ. Adipose tissue-derived stem cells: can impure cell preparations give pure results? *Nephrol Dial Transplant* 2010;25:3805-3807.
8. Gimble JM, Katz AJ, Bunnell BA. Adipose-derived stem cells for regenerative medicine. *Circ Res* 2007;100:1249-1260.
9. Nixon AJ, Dahlgren LA, Haupt JL, et al. Effect of adipose-derived nucleated cell fractions on tendon repair in horses with collagenase-induced tendinitis. *Am J Vet Res* 2008;69:928-937.
10. Namba J, Shimada K, Saito M, et al. Modulation of peritendinous adhesion formation by alginate solution in a rabbit flexor tendon model. *J Biomed Mater Res B Appl Biomater* 2007;80:273-279.
11. Zuk PA, Zhu M, Ashjian P, et al. Human adipose tissue is a source of multipotent stem cells. *Mol Biol Cell* 2002;13:4279-4295.
12. Saygi B, Yildirim Y, Cabukoglu C, et al. The effect of dehydration and irrigation on the healing of Achilles tendon: an experimental study. *Ulus Travma Acil Cerrahi Derg.* 2008;14:103-109.
13. Maffulli N, Moller HD. Optimization of tendon healing. In: Maffulli N, Renström P, Leadbetter WB, Eds. *Tendon injuries: basic science and clinical medicine*. London: Springer, 2005;304-305.
14. Liu SH, Yang RS, al-Shaikh R, et al. Collagen in tendon, ligament, and bone healing. A current review. *Clin Orthop Relat Res* 1995;318:265-278.
15. Dahlgren LA, van der Meulen MC, Bertram JE, et al. Insulin-like growth factor-I improves cellular and molecular aspects of healing in a collagenase-induced model of flexor tendinitis. *J Orthop Res* 2002;20:910-919.
16. James R, Kesturu G, Balian G, et al. Tendon: biology, biomechanics, repair, growth factors, and evolving treatment options. *J Hand Surg Am* 2008;33:102-112.
17. Koob TJ, Summers AP. Tendon--bridging the gap. *Comp Biochem Physiol A Mol Integr Physiol* 2002;133:905-909.
18. Goodpaster T, Legesse-Miller A, Hameed MR, et al. An immunohistochemical method for identifying fibroblasts in formalin-fixed, paraffin-embedded tissue. *J Histochem Cytochem* 2008;56:347-358.
19. Hoffmann A, Pelled G, Turgeman G, et al. Neotendon formation induced by manipulation of the Smad8 signalling pathway in mesenchymal stem cells. *J Clin Invest* 2006;116:940-52.
20. Violini S, Ramelli P, Pisani LF, et al. Horse bone marrow mesenchymal stem cells express embryo stem cell markers and show the ability for tenogenic differentiation by in vitro exposure to BMP-12. *BMC Cell Biol* 2009;10:29.
21. Kryger GS, Chong AK, Costa M, et al. A comparison of tenocytes and mesenchymal stem cells for use in flexor tendon tissue engineering. *J Hand Surg Am* 2007;32:597-605.
22. Nakagami H, Morishita R, Maeda K, et al. Adipose tissue-derived stromal cells as a novel option for regenerative cell therapy. *J Atheroscler Thromb* 2006;13:77-81.
23. Orhan Z, Ozturan K, Guven A, et al. The effect of extracorporeal shock waves on a rat model of injury to tendo Achillis. A histological and biomechanical study. *J Bone Joint Surg Br* 2004;86:613-618.

24. Fadale P, Bluman E, Allen S. Pathophysiology of muscle, tendon, and ligament Injuries In: Schepesis AA, Busconi BD, Eds. *Sports medicine*. Philadelphia: Lippincott Williams & Wilkins, 2006;1-19.
25. Fukuda K. Regeneration of cardiomyocytes from bone marrow: Use of mesenchymal stem cell for cardiovascular tissue engineering. *Cytotechnology* 2003;41:165-175.
26. Toghraie FS, Chenari N, Gholipour MA, et al. Treatment of osteoarthritis with infrapatellar fat pad derived mesenchymal stem cells in Rabbit. *Knee* 2009;18:71-75.
27. Winkler T, von Roth P, Matziolis G, et al. Dose-response relationship of mesenchymal stem cell transplantation and functional regeneration after severe skeletal muscle injury in rats. *Tissue Eng Part A*. 2009;15:487-492.
28. Van Eijk F, Saris DB, Riesle J, et al. Tissue engineering of ligaments: a comparison of bone marrow stromal cells, anterior cruciate ligament, and skin fibroblasts as cell source. *Tissue Eng* 2004;10:893-903.
29. Chong AK, Ang AD, Goh JC, et al. Bone marrow-derived mesenchymal stem cells influence early tendon-healing in a rabbit achilles tendon model. *J Bone Joint Surg Am* 2007;89:74-81.
30. Ouyang HW, Goh JC, Lee EH. Viability of allogeneic bone marrow stromal cells following local delivery into patella tendon in rabbit model. *Cell Transplant* 2004;13:649-657.
31. Smith RK, Korda M, Blunn GW, et al. Isolation and implantation of autologous equine mesenchymal stem cells from bone marrow into the superficial digital flexor tendon as a potential novel treatment. *Equine Vet J* 2003;35:99-102.
32. Pacini S, Spinabella S, Trombi L, et al. Suspension of bone marrow-derived undifferentiated mesenchymal stromal cells for repair of superficial digital flexor tendon in race horses. *Tissue Eng* 2007;13:2949-2955.
33. Javanmardi S, Sarrafzadeh-Rezaei F, Delirezh N, et al. Use of Undifferentiated Cultured Bone Marrow-Derived Mesenchymal Stem Cells for DDF Tendon Injuries Repair in Rabbits: A Quantitative and Qualitative Histopathological Study. *IJVS* 2008;3:51-60.
34. Crovace A, Lacitignola L, Rossi G, et al. Histological and immunohistochemical evaluation of autologous cultured bone marrow mesenchymal stem cells and bone marrow mononucleated cells in collagenase-induced tendinitis of equine superficial digital flexor tendon. *Vet Med Int* 2010:250978.
35. Cancedda R, Bianchi G, Derubeis A, et al. Cell therapy for bone disease: a review of current status. *Stem Cells* 2003;21:610-619.
36. Banfi A, Muraglia A, Dozin B, et al. Proliferation kinetics and differentiation potential of ex vivo expanded human bone marrow stromal cells: Implications for their use in cell therapy. *Exp Hematol* 2000;28:707-715.
37. Uysal AC, Mizuno H. Tendon regeneration and repair with adipose derived stem cells. *Curr Stem Cell Res Ther* 2010;5:161-167.

اثرات تزریق داخل تاندونی سلولهای کشت نشده استرومال واسکولار مشتق از بافت چربی بر روند التیام تاندون در خرگوش: بررسی بافت شناسی و ایمونو هیستوشیمی

مهدی بهفر^۱، فرشید صراف زاده رضایی^۱، رحیم حبنقی^۲، نوروز دلیرز^۳، بهرام دلیرنقده^۱

^۱ گروه علوم درمانگاهی، دانشکده دامپزشکی، دانشگاه ارومیه، ارومیه، ایران.

^۲ گروه پاتوبیولوژی، دانشکده دامپزشکی، دانشگاه ارومیه، ارومیه، ایران.

^۳ گروه بیوتکنولوژی سلولی-مولکولی، انستیتو بیوتکنولوژی، دانشگاه ارومیه، ارومیه، ایران.

هدف- ارزیابی اثرات تزریق داخل تاندونی سلولهای استرومال کشت نشده مشتق از بافت چربی بر روند التیام تاندون

طرح مطالعه- مطالعه آینده نگر توصیفی

حیوانات- در این مطالعه از بیست و پنج قطعه خرگوش نر سفید نیوزلندی با وزن تقریبی ۲/۵ تا ۳ کیلوگرم استفاده شد، که پنج قطعه بعنوان حیوانات دهنده برای استحصال سلولهای استرومال در نظر گرفته شده و بقیه بعنوان حیوانات مدل به گروههای شاهد و درمان تقسیم شدند.

روش کار- مدل جراحی در این مطالعه، ایجاد برش عرضی کامل در قسمت یک سوم میانی تاندون خم کننده عمقی انگشتان در یکی از اندامهای خلفی بود. بلافاصله پس از کارگذاری بخیه، در گروههای درمان و شاهد، بترتیب سلولهای استرومال بدست آمده از هضم آنزیمی بافت چربی و دارو نما بصورت داخل تاندونی در دو انتهای بخیه شده تاندون تزریق شد. اندام مورد جراحی به مدت دو هفته داخل گچ ارتوپدی تثبیت و در هفته های سوم و هشتم پس از جراحی، همگی حیوانات آسان کشی شده و تاندونها تحت بررسی مطالعات بافت شناسی و ایمونو هیستوشیمی قرار گرفتند.

نتایج- یافته های بافت شناسی حاکی از بهبود آرایش رشته های کلاژنی و بلوغ تاندون تازه تشکیل یافته ناشی از تزریق سلولهای استرومال در گروه درمان در هفته های سوم و هشتم پس از جراحی بود. مطالعه ایمونو هیستوشیمی نمونه ها نیز افزایش تجلی کلاژن نوع یک و کاهش تجلی کلاژن نوع سه را در گروه درمانی هفته هشتم نشان داد.

نتیجه گیری و کاربرد بالینی- نتایج این مطالعه نشان داد که تزریق داخل تاندونی سلولهای کشت نشده استرومال واسکولار مشتق از بافت چربی، باعث بهبود خصوصیات ساختاری در روند التیام تاندون می شود و می تواند بعنوان رهیافت جدیدی برای ترمیم جراحات تاندونی مورد استفاده قرار بگیرد.

کلید واژگان- بافت چربی، سلول استرومال، تاندون، بافت شناسی، ایمونو هیستوشیمی.