



Evaluation of Normal Ultrasonographic Findings of Kidney in Raiini Goat

Darioush Vosough*¹, DVSc
Ali Asghar Mozaffari¹, DVSc

¹Department of Clinical Sciences, Faculty of Veterinary Medicine,
Shahid Bahonar University of Kerman, Kerman, IRAN

Abstract

Objective- to assess the normal ultrasonographic findings of kidney in the Raiini goat.

Design- Experimental study.

Animals- 10 female Raiini goats.

Procedures- Necropsy was carried out and Kidneys were measured in length, width, and diameter after fixation in formalin. Ultrasonography was carried out by longitudinal and transversal planes to evaluate all renal structures. Echogenicity and size of cortex, medulla, and renal sinuses were evaluated.

Results- In longitudinal and transverse scans, cortex, medulla and renal sinuses were seen. Renal pyramids could not be counted in ultrasonography.

Conclusion and Clinical Relevance- Evaluation of shape, size and condition of renal tissue is possible by ultrasonography and this study

Key Words- Ultrasonography, Kidney, Raiini Goat.

Introduction

Ultrasonographic study of urinary system is a safe, easy, fast and highly appreciated way for evaluation of kidney, ureter, bladder and urethra and diagnose abnormalities of these structures.^{1,2,3}

Ultrasonography helps us to evaluate changes in kidneys size, status of cortex, medulla and pelvis, existence of massive lesions⁴, hydronephrosis⁵, neoplasia⁶, cystitis⁷, calculies^{8,9,10}, bladder diverticulum⁷, obstructions of lower urinary tracts^{8,10}, and patient response to treatment.

Obviously normal sonographic values of each breed to diagnose the problems are needed.

* Corresponding author:

Darioush Vosough, DVSc

Department of Clinical Sciences, Faculty of Veterinary Medicine, University of Kerman, Iran.

E-mail address: Dvosough@yahoo.com

Raiini goat is an important breed of goat that plays a significant role in wool industry. There is no recorded research using ultrasonography to evaluate the urinary tract of this breed to the authors' knowledge.

The purpose of this study is to assess the normal ultrasonographic findings of kidney in the Raiini goat.

Materials and Methods

10 mature female goats weighing 24 ± 1.8 kg were used in the current study. All the goats were older than 2 years based on dental formula evaluation and they were numbered from 1 to 10. Health status was determined by physical, clinical, and paraclinical examinations. All ultrasonographic evaluations were carried out in standing position. To prepare a better image, the regional skin was cleaned and shaved and then covered with a specific ultrasonographic gel.

In all cases, ultrasonography was done without any alimentary diet, in a standing position and both kidneys could be scanned from the right side of the body and in flank zone right before the 13th rib and in ventral part of transverse process of lumbar vertebrae. Although scan of left kidney was possible from left flank.

To assess the right kidney longitudinally, the transducer was placed of the sublumbar fossa immediately caudal to the last right rib. To assess the left kidney longitudinally, the transducer was placed parallel to lumbar vertebrae on the middle of the left flank.

To evaluation kidneys in transversal sections, the transducer was placed right on the longitudinal axis of each kidney. In all occasions both kidneys were scanned by ultrasonography without any alimentary diet and in standing position with the probe frequency of 5-7 Mhz .

Ultrasonographic examination was done three times in three separate weeks to reduce the error rate. Ultrasonography was done using a CTS-900 unit made in South Korea and a 5-8 MHz linear array transducer .Ultrasonography was carried out by longitudinal and transversal planes to evaluate all renal structures. Echogenicity and size of cortex, medulla, and renal sinuses were evaluated . After sonographic examination, all goats were taken to anatomy department of Veterinary faculty for necropsy examinations . Kidneys were determined in length, width, and diameter after fixation in formalin. In the end, by statistical calculations, all the results of ultrasonography of right and left kidneys were compared with each other using T-test in SPSS software.

Results

Both kidneys were observable from the right flank but from the left flank, only the left one was seen. In longitudinal and transverse scans, cortex, medulla and renal sinuses were seen(Fig.1 to 4). Renal sinuses image was seen in central position with hyper echoic zones which was easily differentiated with hypo echoic cortex and medulla parts on its border (Fig. 2). Medulla was anechoic, although cortex was gray due to higher echogenicity than medulla . In none of the kidneys, capsules couldn't be observed. Renal hiatus was observed as a hyper echoic horse shoe shape in the transversal scans. Observation of ureter was not possible using ultrasonography. Diameter

measurement of empty and full bladder was not possible from abdominal region. Renal pyramids could not be counted in ultrasonography.

Table1. Measurement of length and width of right and left kidneys and cortex and medulla in transverse anatomical section (mm)

Measured parameter	Left kidney	Right kidney
Kidney's length	43.7	44.5
Kidneys width	29.8	30.0
Kidneys diameter	24.7	24.9
Medullary diameter in transversal section	13.3	14.4
Cortical diameter in transversal section	7.8	8.6
Medullary diameter in longitudinal section	25.4	26.6
Cortical diameter in longitudinal section	8.2	8.7

Table2. Variance analysis of measured ultrasonography parameters in right and left kidneys in Raiini goats

Surveyed Index	P Value
Cortical diameter in longitudinal section	0.001
Medullary diameter in longitudinal section	0.210
Kidney's length in longitudinal section	0.007
Kidneys width in longitudinal section	0.000
Medullary diameter in transversal section	0.726
Cortical diameter in transversal section	0.001
Kidneys width in transversal section	0.001

P>0.05 has no significant differences.

P<0.05 has significant differences.

Tables 1 to 2: The above mentioned quantities varied in the right and left kidneys, and there were significant differences among all values of right and left kidneys in ultrasonography, except medullary diameter in longitudinal scan and width of kidney in transversal scan.

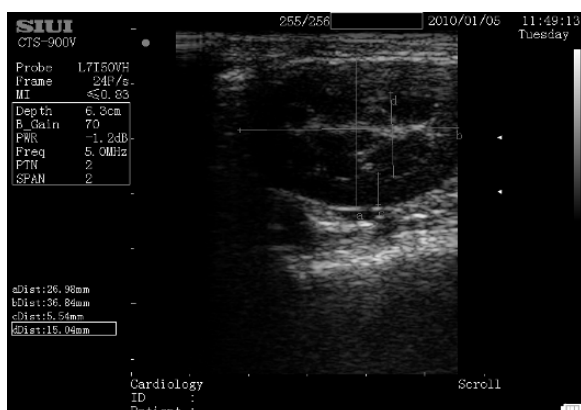

Figure 1. Size of medullary region of right kidney in longitudinal scan

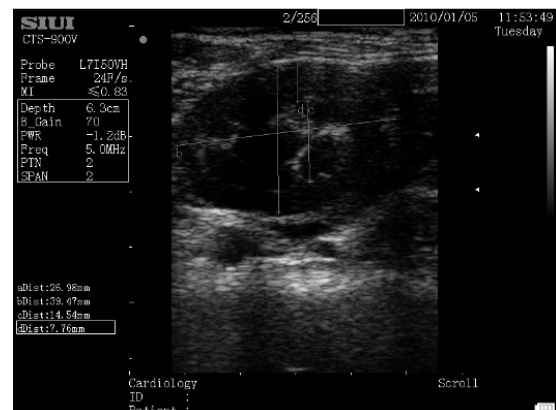


Figure 2. Size of renal medulla & cortex in longitudinal scan

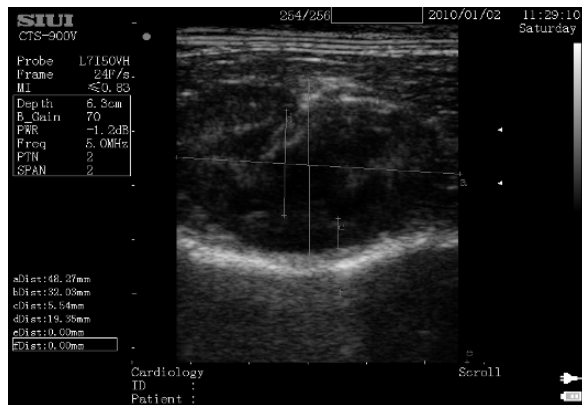


Figure 1. Size of medullary region of right kidney in longitudinal scan

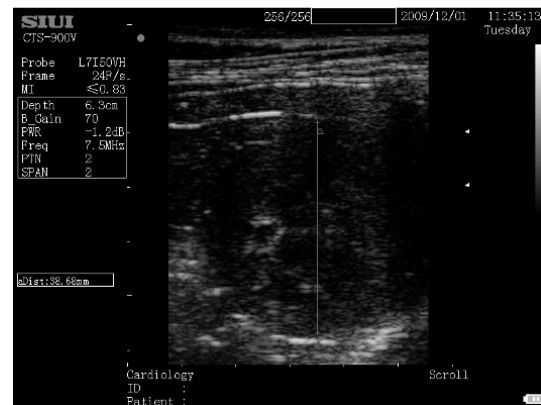


Figure 4. Measurement left kidney most wide region in transverses scan

Discussion

Evaluation of shape, size and condition of renal tissue is possible by ultrasonography²¹. In comparison with radiography, ultrasonography provides the chance to specify little kidneys, liquids and masses around kidneys, and urethral dilation.^{12,13} Secretory urography technique can also be used for anatomical specification, renal function and the function of bladder, however; it is an expensive and dangerous method due to ionizing radiations.^{12,14} It should be taken into consideration that in some cases such as bladder rupture, using ultrasonography is faster, safer, cheaper and more accurate than retrograde cystography and secretory urography.^{7, 11,15} In human¹⁶, dog^{17,18} and horse^{1,19} due to the presence of plenty of gas in the intestinal loops, observation of kidneys using ultrasonography is sometimes hard. Therefore, animals were off fed to decrease the amount of intestinal gases. In sheep no alimentary diet is needed before the ultrasonography of the urinary system possibly due to the anatomical position of intestines in small ruminants and standing position of animal during the ultrasonography procedure.^{1,2,20} In all cases, ultrasonography was done without any alimentary diet, in a standing position and both kidneys could be scanned from the right side of the body and in flank zone right before the 13th rib and in ventral part of transverse process of lumbar vertebrae. In this study considering the anatomical position of the right kidney, which is placed in the ventral part of the transverse process of first three lumbar vertebrae, it was possible to scan it from the 12th intercostal zone and behind the 13th rib. This shows that ultrasound waves are able to orientate to front and rear. So scanning of right kidney was possible from 12th intercostal zone and even 11th intercostal zone which is placed underneath the thoracic vertebrae. Like human²¹, horse¹, dog^{6,17,18} and cat^{22,23} according to this research scanning the left kidney is possible from the left flank. Whereas, in cattle and sheep there was no report about scanning the left kidney from the left flank. Although in this research scanning of left kidney was completely possible from the right flank without any prohibition of other viscera that is compatible with sheep's reports.^{1,2} Therefore, for evaluation of the Raiini goat's kidneys using ultrasonography, it's not necessary to shave the left flank, as both kidneys can be scanned from right flank. The procedure was carried out in goats in standing position just like sheep,

cattle and horse. In this research ultrasonography was done in the ventral part of the 2nd to 4th lumbar vertebrae transverse process. However anatomy sources imply that the left kidney is placed between the 3rd to 5th lumbar vertebrae. That shows some differences between the research and the anatomy sources.^{24,25,26,27} Obviously this proposition has a close relationship with the volume of rumen and position of other viscera. Whereas the volume of rumen is related to time of the animal's repast so though there was no alimentary diet but due to time interval between the last intake and ultrasonography procedure there was a little difference in volume of rumen. It is shown in this research that parabola scan of right kidney with placing the transducer parallel to the 13th rib is possible. To perform transversal scan from its placing the transducer staple on this axis scanning between transverse and dorsal is enough. To parabola scan it is necessary to place the transducer on right flank parallel to lumbar vertebrae and to evaluation its transverse axis, the transducer was put staple on longitudinal axis. In this research it observed that while scanning the left kidney moving the transducer ventilator is easier than right kidney due to existence of 13th rib which prohibits moving the transducer but finding the right kidney was so easier because it's immobile. Goat's kidneys are like sheep's which are not lobulated and the ultrasonographic image of them is similar to kidneys of human, dog, and cat. In our cases, renal sinuses were more hyper echoic than cortex. Although the medullary part was more hypo echoic than the cortex, it was less echogenic than the cortex which is compatible with previous reports.^{12, 21, 22, 23} Renal capsule can be scanned according to the type and quality of ultrasonography machine. But in this study in none of the cases, capsule was seen. Ureter and its opening in bladder were not observable in this study. In dog to observe this part, diuretics are used and by increasing urine flow and using high resolution ultrasonography machines with high frequency transducers this part would be observable.²⁸

References

1. Kiper ML, Traub- Dargatz JL, and Wrigley, R. H. Renal ultrasonography in horses. Compendium on continuing Education for Practicing Ultrasonography of the urinary tract of female sheep. *Am J Vet Res* 1990;53:1434-1439.
2. Knauff PS, Sonographische darstellung von nieren, uretern und harnblase beim hound unter besondere Berucksichtigung der messung ihrer lage, Crosse und hirer halts(thesis). Giessen, Germany university of Giessen. Quoted By: Braun, u., Schaefer, u., Geber, D. Ultrasonography of the urinary tract of female sheep. *American Journal of Veterinary Research* 1990;53(10):1434- 1439.
3. Moghaddam, G.A. In vitro ultrasonography of sheep kidney. 24th world Veterinary Congress Tunisia.(Abstract).(2002).
4. Lane, V.M., Leder, R.L. Unilateral nephrectomy for chronic Hemophilus somuns – associated nephritis in cow. Compendium on continuing Education for Practicing Veterinarian, (1988); 10: 520-527. Quoted By: Hayashi, H., Biller, D.S., Rings, D. M and Miyabyashi, T. Ultrasonographic diagnosis of pyelonephritis in cow. *Journal of American Veterinary Medical Association.*, (1994); 205(5): 736-738.
5. Harrison, G.D., Biller, D.S. and Wilson, D. G. Castlemun W L. Ultrasonographic diagnosis of hydronephrosis in cow. *Veterinary Radiology and Ultrasound*, (1992); 33: 49-51.

6. Konde, L. J., Wrigley, R.H. and Park, R. D. Sonographic appearance of renal neoplasia in the sog. *Veterinary Radiology*, .(1985); 26: 74-81.
7. Leveille, R. Ultrasonography of urinary bladder disorder. *Veterinary Clinics of North America: Small Animal practice*, .(1998); 28: 799-821.
8. Fetcher, A. Renal disease in cattle. II. Clinical sings diagnosis and treatment. *Compendium on Continuing Education for Practicing Veterinartian*, (1989); 8: S338-S344. Quoted by: Braun, U., Shefer, U., Fohn, J. Urinary tract ultrasonography in normal ram with obstructive urolithiasis. *Canadian Veterinary Journal*, .(1992); 33: 654-659.
9. Juzwiak, J.S., Bain, F. T. and Slone, D. E. Unilateral nephrectomy for treatment of chronic hematuria due to nephrolithiasis in a colt. *Canadian Veterinary Journal*, (1988); 29: 931-933.
10. Kimberling, C. V., Arnold, K. S. Disease of the urinary system of sheep and goats. *Veterinary Clinics of North America (Large animal practice)* , .(1983); 5: 637- 655 Quoted by: Braun. U., Schefer, U. and Fohn, J. Urinary tract ultrasonography in normal ram with obstructive urolithiasis. *Canadian Veterinary Journal*, .(1992); 33: 654- 659.
11. Redostits, O.M., Blood, D.C. and Gay, C.C.. *Veterinary Medicine*. 9th edition. Bailler Tindall. (2000); PP:492-499.
12. Nyland, T.G., Matton, J.S *Small Animal Diagnostic Ultrasound*, 2th edition. W.B., Saunders Company. Philadelphia. .(2002); PP: 158-182.
13. Rantanen, N.W. Diseases of the kidney. *Veterinary Clinics of North America: Equine Practice*. .(1986);2: 105-114.
14. Neurwith, L., Mahaffey, M. and Crowell, W.(1993). Comparison excretory urogeraphy and ultrasonography for detection of experimentally induced pyelonephritis in dogs. *American Journal of Veterinary Research*, 54: 660-669.
15. Leveille, R., Biller, D.S., Parting ton, B.P. and Miyabashi. Sonographic investigation of transitional cell carcinoma of urinary bladder in small animals. *Veterinary Radiology and Ultrasound*, (1992); 33: 103-104.
16. Swobodonik, W., Herman, M and Altwein, J. E. *Atlasder ultraschallanatomie; sonographische normal be fun deals Grundlage der diagnostic*. Stuttgart, New York: George thieme verlag, (1992); 343-345., U., Shafer, Geber, D. Ultrasonography of urinary tract of female sheep. *American Journal of Veterinary Research*, (1992); 53(10): 1434- 1439.
17. Konde, L. J., Wrigley, R. H. and Park, R. D., Ultrasonographic anatomy of normal canine kidney. *Veterinary Radiology*, (1984); 25: 173- 178.
18. Wood, A. K. W., McCarthy, P.H. Ultrasonographic. Anatomic correlation and an imaging protocol of normal canine kidney. *American Journal of Veterinary Research*, .(1990); 51: 103-108.
19. Pennick, D. G., Eisenberg, H.M. and Teusher, E. E. Equine renal ultrasonography: normal and abnormal. *Veterinary Radiology*, (1986); 27: 81-84.
20. Braun, U., Shefer, U. and Geber, D. Ultrasonography of the urinary tract of female sheep. *American journal of Veterinary Research*, .(1992); 53(10): 1434-1439.
21. Swobodonik, W., Herman, M and Altwein, J. E. *Atlasder ultraschallanatomie; sonographische normal be fun deals Grundlage der diagnostic*. Stuttgart, New York: George thieme verlag, (1992); 343-345. Quoted by: Braun, U., Shafer, Geber, D. Ultrasonography of urinary tract of female sheep. *American Journal of Veterinary Research*, (1992); 53(10): 1434- 1439.

22. Walter, P.A., Johnston, G. R. and Feeney, D. A. Renal ultrasonography in healthy cats. *American Journal of Veterinary Research*, (1987); 78: 600-607.
23. Walter, P. A., Feeney, D. A. and Johnston, G. R. Feline renal ultrasonography: quantitative analyses of imaged anatomy. *American Journal of Veterinary Research*, (1987); 48: 596-599.
24. May, N. D. S. *The Anatomy of Sheep*. 3rd edition: University of queen land-press. St.Lucia .Australia, (1970); PP: 94- 95.
25. Nickle, R., Schmmer, A. and Seiferle, E. *The Anatomy of Domestic Animal*. Vol 2. Berlin: Verlag Paul Parey.PP,(1973); 291- 293.
26. Sisson, S., Grossman, J. D. *The Anatomy of Domestic Animal*. 5th edition. Vol 1: W. B., Saunders Company, Philadephia. (1975); PP: 934-939.
27. Popesko, P. *Atlas of Topographical Anatomy of the Domestic Animals* 2th edition: W.B., Saunders Company, Philadelphia. .(1985);PP: 75-81.
28. Lamb, C. R., Gregore, S. P. Ultrasonographic finging in dogs with ectopic ureter. *Veterinary Radiology and Ultrasound*, .(1998); 39:218-223.

بررسی دستگاه ادراری بز رایینی به کمک اولتراسونوگرافی

داریوش وثوق*، علی اصغر مظفری

گروه علوم درمانگاهی، دانشکده دامپزشکی، دانشگاه شهید باهنر کرمان، کرمان، ایران.

هدف - بررسی یافته‌های اولتراسونوگرافی دستگاه ادراری بز رایینی

طرح مطالعه - مطالعه تجربی

حیوانات - ده رأس بز رایینی ماده

روش کار - ۱۰ رأس بز رایینی ماده بالغ و سالم مورد مطالعه قرار گرفتند. جهت ارزیابی تمامی ساختمان کلیه، اولتراسونوگرافی از کلیه‌ها در مقاطع طولی و عرضی انجام گرفت. اکوژنسیته و اندازه‌های کورتکس، مدولا و سینوس‌های کلیوی مورد بررسی اولتراسونوگرافی قرار گرفتند.

نتایج - امکان مشاهده‌ی کلیه‌های راست و چپ از تهی‌گاه سمت راست و تهی‌گاه سمت چپ برای کلیه وجود داشت. در اسکن‌های طولی و عرضی کورتکس، مدولا و سینوس‌های کلیوی قابل مشاهده و ارزیابی بوده‌اند. همچنین هرمهای کلیوی در مدولا نیز به صورت قابل شمارش مشاهده نشدند.

نتیجه‌گیری و کاربرد بالینی - به کمک اولتراسونوگرافی می‌توان شکل، اندازه و وضعیت نسج داخلی کلیه‌ها را در این نژاد بز مورد ارزیابی قرار داد و می‌تواند تحقیق فوق در شناسایی بیماری‌های کلیوی در این نژاد به‌عنوان یک منبع مورد استفاده قرار گیرد.

کلید واژگان - اولتراسونوگرافی، کلیه، بز رایینی، آناتومی