



Normal Echocardiographic Findings in Healthy Pigeons

Majid Masoudifard^{*1}, Vajiheh Rahimi Bidgoli¹, Seyed Ahmad Madani², Alireza Vajhi¹,
Somayye Davoodipoor¹, Yasamin Vali¹

Abstract

Objective- The purpose of this study was to investigate the feasibility of performing echocardiography in apparently healthy pigeons, and measurement of the quantitative cardiac indices using B-mode and Doppler techniques.

Design- Experimental study

Animals- Ten apparently healthy pigeons

Procedures- Echocardiography was performed in ventromedian and right parasternal approaches after evaluating pigeons' heart radiographically. Cardiac chambers, valves and hemodynamic parameters were evaluated subjectively and objectively by the B-Mode, color and pulse-wave Doppler techniques. The mean and the standard deviation of the quantitative measurements were presented as the objective as well as subjective results

Results- The right parasternal approach was more efficient than the ventromedian approach in obtaining high-quality image. Evaluation of the ventricles, atria and aorta was possible objectively by B-mode technique. Valvular function and quality of the blood flow was assessable subjectively by color Doppler technique. Measuring the hemodynamic parameters in the atrioventricular and aortic valves was feasible as quantitative parameters using pulse-wave Doppler echocardiography. No gross lesions were detected at necropsy.

Conclusion and Clinical Relevance- Echocardiography showed high accuracy and reliability in determination of avian cardiac indices. Therefore it can be a useful noninvasive diagnostic tool for morphological and functional evaluation of avian cardiac system and can be helpful in diagnosis of avian cardiac disorders.

Keywords- Echocardiography, Ultrasonography, Doppler, Pigeon, bird.

Introduction

The cardiovascular system of birds has great adaptation to their specific demands for flight. They have an efficient circulatory system regarding the cardiac anatomy and physiology.¹ Cardiovascular diseases and disorders are common in pet birds due to their restricted exercise, poor diet, and abnormal climate in captivity.² It is difficult to diagnose cardiovascular diseases in live birds and most cardiac diseases are diagnosed at necropsy. Physical examination and laboratory tests have minimal value in the diagnosis of avian heart

diseases.³ Imaging techniques such as radiography, ultrasonography (US), and electrocardiography (ECG) can be alternative diagnostic tools in the cardiovascular diseases.¹ While radiography and ECG have less value in evaluation of internal structure of the heart, echocardiography (Echo) can be used for both external and internal structures. Echo is considered as a valuable noninvasive technique for evaluation of inner structure, size, and motility of the heart.⁴ Therefore, Echo can be used for cardiac functional and morphological assessment and for diagnosis of some cardiovascular abnormalities.⁵ The small size of some avian patients limits the application of Echo in those species. On the other hand some anatomical specificity such as the presence of air sacs can limit the use of ultrasonographic techniques in birds.⁶ Despite the initial evidence for Echo applicability in avian medicine, the reproducibility of Echo results and quantitative data analysis for functional and anatomical

¹Department of Surgery and Radiology, Faculty of Veterinary Medicine, University of Tehran, Tehran, Iran.

²Department of Animal and Poultry Health and Nutrition, Faculty of Veterinary Medicine, University of Tehran, Tehran, Iran.

Address all correspondence to Majid Masoudifard (DVM, DVSc)
E-mail: mmfard@ut.ac.ir

Received 18 Feb 2016; accepted 19 Feb 2017

Echo measurements in avian species are scant in the literature. The purpose of this study was to investigate the feasibility of performing Echo in apparently healthy pigeons, and measurement of quantitative cardiac indices using B-mode and Doppler techniques.

Material and Methods

Ten apparently healthy pigeons were included to present study. Clinical examination was performed and body weight was measured. The shape and the size of the pigeons' hearts were evaluated by radiography in right lateral and ventrodorsal views. Birds were fasted for ten hours before US examination to reduce the impact of gastrointestinal contents on the penetration of US waves.⁷ The birds were restrained on an acrylic plate in upright position and dorsal recumbency.⁵ Only a few feathers were plucked from the area of contact as it required. To obtain a clear image and reduce the artifacts, commercially available water-soluble acoustic gel was used.

The pigeons were examined echocardiographically using a Sonosite Micromaxx ultrasound system (Sonosite Inc., Bothell, WA, USA). A phased array pediatric probe with a frequency of 4-8 MHz (Sonosite Inc., Bothell, WA, USA) was used. Pigeons' hearts were evaluated using ventromedian and right parasternal approaches. In ventromedian approach, the transducer was coupled in the midline directly behind the sternum and beam plane was directed craniodorsally towards the heart. In right parasternal approach, the transducer was placed on the right side of the body, between the last rib and the pelvic bones, and beam plane was directed craniomedially.

To measure the cardiac parameters in B-mode technique, cardiac long axis view in the right parasternal approach was obtained. Measurements were taken at the largest and at the smallest dimensions of the chambers in diastole and systole, respectively, using the inner edge method. Cardiac Systolic and diastolic cycle were determined subjectively.

Measured parameters in 2-D images were consisted of length of the left ventricle in diastole (LVLD) and in systole (LVLS), width of the left ventricle in diastole (LVTD) and in systole (LVTS), length of the right ventricle in diastole (RVLD) and in systole (RVLS), width of the right ventricle in diastole (RVTD) and in systole (RVTS), length of the left atria (LAL), width of the left atria (LAT) and aortic diameter (AOD). Subsequently, the end systolic (ESV) and the end diastolic left ventricular volume (EDV), fractional shortening (FS) and ejection fraction of the left ventricle (EF), stroke volume (SV) and ratio of width to length of the left ventricle in systole and diastole were calculated by the replacement of the parameter values measured in the following formula:^{4, 8}

$$EDV (ml) = 0.72 \times LVLD (mm) \times LVTD (mm)$$

$$ESV (mm) = 0.72 \times LVLS (mm) \times LVTS (mm)$$

$$FS (\%) = (LVTD - LVTS) \times 100 / LVTD$$

$$EF (\%) = (100 - ESV) \times 100 / EDV$$

$$SV (ml) = EDV (ml) - ESV (ml)$$

The pattern of blood flow in atrioventricular valves and aortic valve was evaluated in color Doppler technique. In pulsed wave Doppler echocardiography, velocity of blood flow, velocity-time integral and pressure gradient in atrioventricular valves and aortic valve were measured. Also pressure created in right ventricle during systole (RVSP) was measured. For measuring these parameters, one millimeter pulsed wave Doppler gate was used at the location of atrioventricular and aortic valves. Distribution of the data was showed in a Box plot diagram, and thus the data which were out of range have been deleted. The mean and standard deviation of the data were calculated using the Microsoft Excel software.

Results

In pigeons, the right parasternal approach was more efficient in obtaining high-quality image compared to the ventromedian approach. The left lateral window was not suitable for Echo due to the presence of gizzard between the heart and the transducer. In B mode Echo, both long axis and semi-transverse views of the heart were investigated (Figs 1, 2); however semi-transverse view was seen only in one case and no measurements have been done in this view. It was impossible to obtain images from widest part of the pigeons' heart and subsequently it was not practical to perform M-mode Echo. In two-dimensional images of the long axis view, left ventricle and atrium, right ventricle and atrium and aorta could be seen as anechoic structures (Fig 1). Also, motion of the left atrioventricular valve, the right muscular atrioventricular valve, the aortic valve and interventricular septum were clearly visible (Fig 3).

Measured parameter values in B-mode technique have been shown in tables 1 and 2.

In color Doppler echo, no regurgitation or turbulence of blood flow in the left and right atrioventricular valves and aortic valve were observed (Fig 4A, 5A, 6A).

Measured parameter values in pulsed wave Echo have been shown in table 3.

The maximum blood flow velocity (V max) and the maximum pressure gradient (PG max) parameters in aortic valve were higher than that in the left and right atrioventricular valves. The right ventricular systolic pressure (RVSP) and the aortic valve pressure gradient were both in the same range, and were higher than the right and left atrioventricular valves gradient pressures. Results of the velocity-time integral parameters measured in the present study showed that the value of this parameter in the aortic valve is more than that in the left atrioventricular valve.

Table 1. Measured parameter values in B-mode echocardiography in 10 healthy pigeons.

Measured parameter	Abbreviation (unit)	Mean \pm SD*
Left ventricle longitudinal diameter diastole	LVLD (mm)	18.43 \pm 1.14
Left ventricle longitudinal diameter systole	LVLS (mm)	12.9 \pm 2.61
Left ventricle transverse diameter diastole	LVTD (mm)	7.31 \pm 0.52
Left ventricle transverse diameter systole	LVTS (mm)	5.73 \pm 0.49
Right ventricle longitudinal diameter diastole	RVLD (mm)	10.8 \pm 1.93
Right ventricle longitudinal diameter systole	RVLS (mm)	7.92 \pm 1.89
Right ventricle transverse diameter diastole	RVTD (mm)	4.3 \pm 0.61
Right ventricle transverse diameter systole	RVTS (mm)	3.18 \pm 0.75
Left atrium longitudinal diameter	LAL (mm)	6.94 \pm 1.49
Left atrium transverse diameter	LAT (mm)	6.71 \pm 1
Aorta diameter	AOD (mm)	4.46 \pm 0.69

*Standard deviation

Table 2. Functional parameter values calculated in the echocardiography of 10 healthy pigeons.

Functional parameters	Abbreviations (unit)	Mean \pm SD*
End diastolic volume	EDV (ml)	97.67 \pm 12.05
End systolic volume	ESV (ml)	57.23 \pm 8.3
Ejection fraction	EF (%)	39.76 \pm 9.85
Fractional shortening	FS (%)	22.03 \pm 5.66
Stroke volume	SV (ml)	41.98 \pm 11.43
LVTD / LVLD	Ratio	0.40 \pm 0.04
LVTS / LVLS	Ratio	0.42 \pm 0.05

*Standard deviation

Table 3. Measured parameter values in pulsed wave echocardiography of 10 healthy pigeons.

Parameters	Abbreviations (unit)	Aortic valve	Left atrioventricular valve	Right atrioventricular valve
Velocity time integral	VTI (cm)	5.06 \pm 0.8	2.31 \pm 0.5	–
Maximum velocity	Vmax (cm/s)	115.61 \pm 15.9	48.51 \pm 10.3	33.16 \pm 7.6
Maximum pressure gradient	PGmax (mmHg)	5.1 \pm 1	0.99 \pm 0.4	0.46 \pm 0.2
Velocity mean	Vmean (cm/s)	58.04 \pm 6.3	27.23 \pm 5	–
Pressure gradient Mean	PGmean (mmHg)	1.37 \pm 0.3	0.31 \pm 0.1	–
Right ventricular systolic pressure	RVSP (mmHg)	–	–	5.46 \pm 0.2

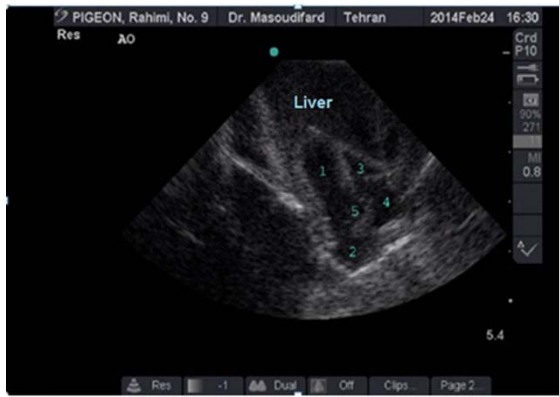

Figure 1. Two dimensional echocardiogram of the long axis view using the right parasternal approach in a healthy pigeon. 1:Left ventricle, 2:Left atrium, 3:Right ventricle, 4:Right atrium, 5: Aorta.

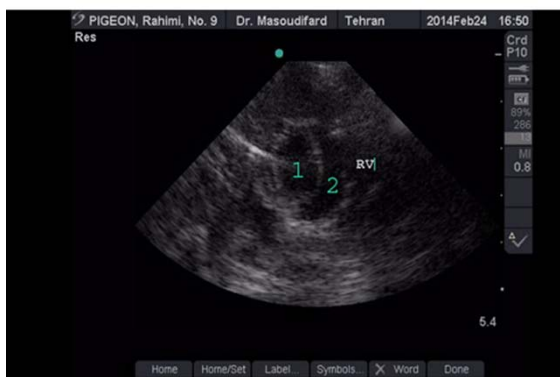

Figure 2. Two-dimensional echocardiogram of the semi-transverse view using the right parasternal in a healthy pigeon. 1:Ventricle, 2: Atrium.

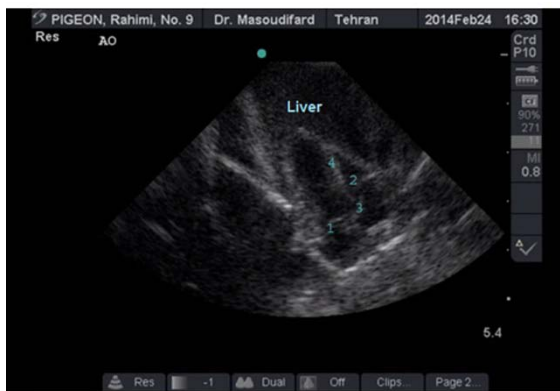

Figure 3. Two-dimensional echocardiogram of the long axis view using the right parasternal approach in a healthy pigeon. 1: Left atrioventricular valve, 2: Right muscular atrioventricular valve, 3: Aortic valve, 4: Interventricular septum.

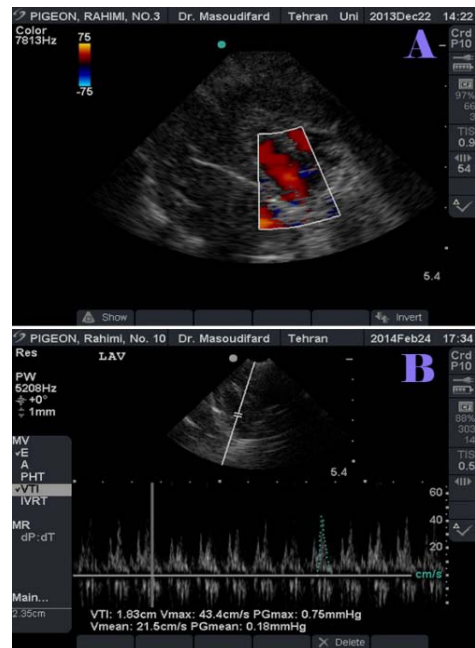

Figure 4. (A) Color Doppler echocardiographic image of a healthy pigeon using the right parasternal approach. Red color represents left atrioventricular flow during diastole without any turbulence. (B) Pulsed wave Doppler echocardiographic image of a healthy pigeon using the right parasternal approach. One millimeter Doppler gate was placed at the location of the left atrioventricular valve.

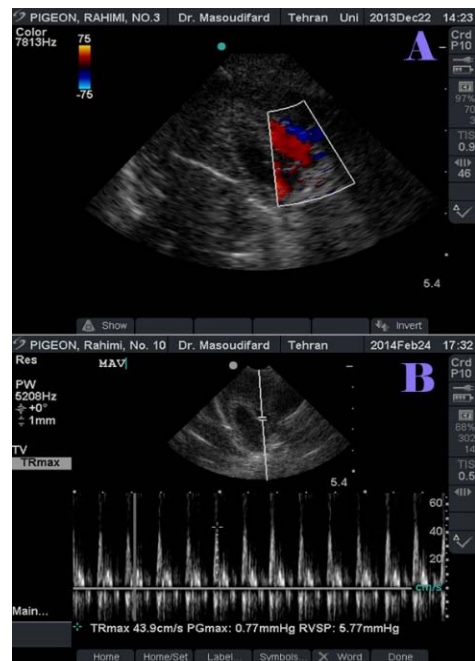


Figure 5. (A) Color Doppler echocardiographic image of a healthy pigeon using the right parasternal approach. Red color represents right atrioventricular flow during diastole without any turbulence. (B) Pulsed wave Doppler echocardiographic image of a healthy pigeon using the right parasternal approach. One millimeter Doppler gate was placed at the location of the right atrioventricular valve.

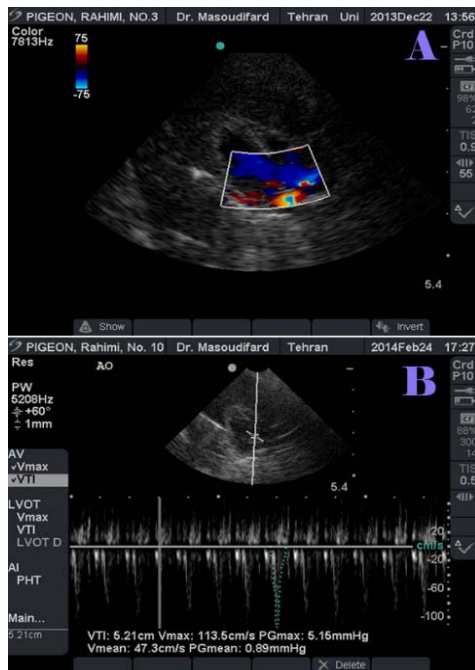

Figure 6. (A) Color Doppler echocardiographic image of a healthy pigeon using the right parasternal approach. Blue color represents outflow from the left ventricle through the aorta during systole without any turbulence of flow. (B) Pulsed wave Doppler echocardiographic image of a healthy pigeon using the right parasternal approach. One millimeter Doppler gate was placed at the location of the aortic valve.

Discussion and conclusion

In the current study, different echocardiographic parameters including LVL, LVTD, LVLS, LVTS, RVLD, RVT, RVLS, RVTS, LAL, LAT and AOD were measured in long axis view of parasternal approach in apparently healthy pigeons. Subsequently, the end systolic and end diastolic left ventricular volume, fractional shortening and ejection fraction of the left ventricle, stroke volume and ratio of width to length of the left ventricle in systole and diastole were calculated. The pattern of blood flow in atrioventricular valves and aortic valve was evaluated in color Doppler technique. This technique was very effective in detection of the valvular insufficiencies which lead to regurgitation or turbulence of blood flow. In this study, no color interference representing the regurgitation or turbulence was observed in the cases. In pulsed wave Doppler Eho, velocity of blood flow, velocity-time integral and pressure gradient in atrioventricular valves and aortic valve were evaluated.

Owing to the presence of sufficient space between the last rib and the pelvic bones in pigeons, right parasternal approach was promising. The ventromedian approach in these birds showed less advantage due to the presence of an elongated, strongly curved sternum. In contrast in psittacine birds, ventromedian approach was reported to be more suitable than in pigeon.⁴ With this approach, the

heart can be presented in two longitudinal views, which are perpendicular to each other: the vertical view (two-chamber view) and the horizontal view (four-chamber view).^{5, 8}

Measuring the chambers dimensions could be helpful in determining the chamber enlargement and dilation. Left ventricular dilation increases ratio of width to length. Measured chambers dimensions in the current study were conforming to presented values for pigeon in other researches,^{4,5} and were less than measured values in psittacine birds.^{4,5,8} The larger cardiac mass in psittacine compared to pigeon might lead to higher chamber dimensions.

Pees *et al.*, 2005, presented reference values for the diastolic inflow into the left and right ventricle and the systolic outflow into the aorta in psittacine birds. The outflow velocity was significantly higher than the inflow velocities, which is caused by the shorter ejection time and the smaller diameter of the aortic root.⁵ In the current study, the pulsed wave spectral Doppler was used and blood flow velocity, pressure gradient and VTI parameters were measured in cardiac valves of ten pigeons without apparent cardiac abnormalities. To the best of author's knowledge these parameters were not previously measured in birds. Results of the pulsed wave spectral Doppler in the present study showed that the blood flow velocity and gradient pressure in the aortic valve were more than that in the left and right atrioventricular valves. Higher blood velocity in aortic valve compared to the atrioventricular valves could be caused by shorter ejection time and smaller diameter of the aortic root, while higher gradient pressure in aortic valve compared to the atrioventricular valves is due to the fact that outflow into the aorta occurs in the cardiac systolic phase, and forms systemic blood circulation. Pressure gradient can help the detection of obstructive lesions in the vessels and valvular narrowing.

The right ventricular systolic pressure (RVSP) and the aortic valve pressure gradient were both in the same range, and were higher than the right and left atrioventricular valves gradient pressures. This is because of the outflow into the aorta and pulmonary artery occurs in the ventricular systolic phase, while the passage of blood from the right and left atrioventricular valves occurs in the ventricular diastolic phase. Therefore, the pressure created in aortic valve and in right ventricle during the systole is more than the pressure created in the right and left atrioventricular valve during the diastole.

Velocity-time integral (VTI) is indicating mileage blood flow. If mileage blood flow in one minute is multiplied in cross section of the valve, valve output per minute is obtained. Therefore, measurement of the velocity-time integral is considered as a method for determining cardiac output. In present study, because blood volume passes through the left atrioventricular valve is equal with the volume of blood ejected from the aortic valve

and diameter of the aortic root is smaller than cross section of the left atrioventricular valve, VTI in the aortic valve was higher than that in the left atrioventricular valve.

In previous research conducted by Pees *et al.*, 2004, formula were presented for calculating the parameters such as FS, EF, and SV. FS% in psittacine birds was 23.1 ± 4.6 ⁸, which is slightly more than the values found in the present study in pigeons as 22.03 ± 5.66 . Yadegary *et al.*, 2013, examined 25 apparently healthy male ostriches to establish normal reference echocardiographic values. Echo was performed from the second and third intercostals space and over the sternum by M-mode technique.⁹ As it is expected the measured values regarding the internal diameter of the chambers in ostrich were higher than in pigeon. Calculated %FS in ostrich showed the value of 56.29 ± 2.68 , that is higher than measured %FS in pigeon.

Gyenai *et al.*, 2012, used Echo in turkey poults from hatch to 28 days of age to identify the dilation cardiomyopathy (DCM). To induce DCM, feed containing furazolidone was fed to turkey poults from one to 28 days-of-age. Some Echo parameters like LVIDd and LVISd differed between poults on normal and furazolidone containing diets as early as 7 days-of-age¹⁰. The %FS in normal poults was %60, which is significantly higher than measured %FS in pigeons in the present study.

Krautwald-Junghanns *et al.*, 2002, examined the heart of 108 racing pigeons of the breed Bricoux. The birds were divided into two groups. One group those kept in aviaries (untrained) and the other, racing birds. Both cardiac dimensions and functional parameters in these two groups differed significantly.¹¹

The result of the present study demonstrated that the Echo has high accuracy and reliability in determination of avian cardiac indices. The Echo values measured in the present study could be applied as the reference values in the pigeons without cardiac pathologies and consequently they can be used for diagnosis of cardiac abnormalities. Therefore it could be very useful noninvasive diagnostic tool for morphological and functional evaluation of avian cardiac system. The echocardiography can also be used in the diagnosis of cardiovascular abnormalities in avian species. Further studies and clinical trials are required to establish the detailed echocardiographic parameters of different avian species in both healthy and diseased situation.

References

1. Strunk A, Wilson GH. Avian cardiology. *The Veterinary Clinics Exotic Animal Practice*, 2003; 6:1-28.
2. DeWit M, Schoemaker NJ. Clinical Approach to avian cardiac disease. *Seminars in Avian and Exotic Pet Medicine*, 2005; 14:1-6.
3. Pees M, Krautwald-Junghanns ME. Cardiovascular physiology and diseases of pet birds. *Veterinary Clinics Exotic Animal practice*, 2009; 12:81-97.
4. Krautwald-Junghanns ME, Schulz M, Hagner D. Transcoelomic twodimensional echocardiography in the avian patient. *Journal of Avian Medicine and Surgery*, 1995; 9:19-31.
5. Pees M, Krautwald-Junghanns ME. Avian Echocardiography. *Seminars in Avian and Exotic Pet Medicine*, 2005; 14(1):14-21.
6. Krautwald-Junghanns ME, Pees M, Reese S, Tully T. Diagnostic Imaging of Exotic Pets, Birds. Small Mammals. Reptiles. Schluetersche; 2009.
7. Pees M, Krautwald-Junghanns ME, Straub J. Evaluating and treating the cardiovascular system. In: Harrison GJ, Lightfoot T eds. *Clinical avian medicine*. Spix publishing; 2006; 379-94.
8. Pees M, Straub J, Krautwald-Junghanns ME. Echocardiographic examinations of 60 African grey parrots and 30 other psittacine birds. *Veterinary Records*, 2004; 155:73-6.
9. Yadegari M, Rezakhani A, Gholami Ahangaran M. Normal Echocardiographic findings in four month old male ostrich (*Struthio camelus*). *Kafkas Universitesi Veteriner Fakultesi Dergisi*, 2013; 19:995-999.
10. Gyenai K, Kamara D, Geng T, Lee-Pyle R, Pierson F, Larsen C, Smith E. An assessment of echocardiography as a diagnostic tool for dilated cardiomyopathy in turkey (*Meleagris gallopavo*). *American Journal of Animal and Veterinary Sciences*, 2012; 7: 120-125.
11. Krautwald-Junghanns ME, Pees M, Schutterlem N. Echocardiographic examinations in unsedated racing pigeons (*Columbia livia forma domestica*) with special consideration for the physical training. *Berliner und Münchener Tierärztliche Wochenschrift*, 2002; 115: 221-224.

چکیده

یافته‌های اکوکاردیوگرافی طبیعی در کبوترهای سالم

مجید مسعودی فرد*^۱، وجیهه رحیمی بیدگلی^۱، سید احمد مدنی^۲، علیرضا وجهی^۱، سمیه داوودیپور^۱، یاسمین والی^۱

^۱ گروه جراحی و رادیولوژی، دانشکده دامپزشکی دانشگاه تهران، تهران، ایران.
^۲ گروه بهداشت و تغذیه دام و طیور، دانشکده دامپزشکی دانشگاه تهران، تهران، ایران

هدف- هدف از تحقیق حاضر بررسی امکان انجام اکوکاردیوگرافی در کبوترهای به‌ظاهر سالم، و اندازه‌گیری شاخص‌های قلبی کمی با استفاده از تکنیک‌های مد روشنایی و داپلر بود.

طرح- مطالعه تجربی

حیوانات- ۱۰ قطعه کبوتر به‌ظاهر سالم

روش کار- برای این منظور، بعد از ارزیابی رادیوگرافی قلب کبوترها، اکوکاردیوگرافی در دو رهیافت شکمی میانی و اطراف جناغی راست انجام شد. حفرات قلبی، دریچه‌ها و پارامترهای همودینامیک به‌صورت چشمی و عددی توسط تکنیک‌های مد روشنایی، داپلر رنگی و داپلر طیفی مورد ارزیابی قرار گرفتند. سپس میانگین و انحراف معیار اندازه‌گیری‌های کمی به‌عنوان نتایج عددی همانند نتایج چشمی ارائه شدند.

نتایج- رهیافت اطراف جناغی راست در مقایسه با رهیافت شکمی میانی در به‌دست آوردن تصاویر با کیفیت بالا بسیار مؤثر گزارش گردید. ارزیابی ساختار دهلیزها، بطن‌ها و آئورت بصورت پارامترهای کمی توسط تکنیک مد روشنایی امکان‌پذیر بوده و عملکرد دریچه‌ها و کیفیت جریان خون به‌صورت چشمی به‌وسیله تکنیک داپلر رنگی قابل ارزیابی می‌باشد. همچنین اندازه‌گیری پارامترهای همودینامیک در محل دریچه‌های دهلیزی بطنی راست و چپ و دریچه آئورت به‌صورت عددی توسط اکوکاردیوگرافی داپلر طیفی محاسبه و گزارش گردید. **نتیجه‌گیری و اهمیت بالینی-** اکوکاردیوگرافی در تعیین شاخص‌های قلبی پرندگان از دقت و اعتبار بالایی برخوردار است. بنابراین به‌عنوان یک ابزار تشخیصی غیرتهاجمی برای ارزیابی مورفولوژیکی و عملکردی سیستم قلبی و تشخیص ناهنجاری‌های قلبی عروقی بسیار مفید می‌باشد.

کلمات کلیدی- اکوکاردیوگرافی، اولتراسونوگرافی، داپلر، کبوتر، پرند.