



## The Evaluation of Topical Administration of Different Doses of Lintbells Oil on Circular Excisional Wound Healing in Experimental Models

Mohammad Reza Farahpour\*

### Abstract

**Objective-** This study aimed to investigate the effect of topical administration of lintbells oil (LBOC) on wound contraction as well as healing process.

**Design-** Experimental study.

**Animals-** 60 Male Swiss albino mice.

**Procedures-** Animals were randomly divided into 5 groups (NO=12) including; vehicle-received negative control, pure oil-received and test group. The animals in treatment group subdivided into two groups as 2% cream-treated (LBOC 2%) and 4% cream-treated (LBOC 4%). Two circular full thickness skin defects were made, in both sides of the backbone, 1 cm away from the midline and 2 cm away from each other with a 5-mm-biopsy punch. Using graph paper, the Percentage of wound contraction measured at 3<sup>rd</sup>, 6<sup>th</sup>, 9<sup>th</sup> and 12<sup>th</sup> days after surgery. Tissue samples were obtained at the 3<sup>rd</sup>, 6<sup>th</sup> and 12<sup>th</sup> days post-wounding, from all groups and stained with Masson's trichrome and studied under light microscope.

**Results-** In LBOC treated groups, the healing process shortened significantly, which was revealed with rapid reduction of wound area. Histological observations revealed that, LBOC in form of 2% formulation remarkably reduced inflammatory cells infiltration, enhanced collagen deposition and facilitated the epithelialization versus other groups.

**Conclusion and Clinical Relevance-** In conclusion, our data showed that lintbells oil, especially in 2% doses, promotes wound contraction ratio and facilitated the healing processes by inhibiting the inflammatory stage and stimulated the proliferative phase by enhancing the fibroblasts distribution and/or proliferation.

**Key Words-** Lintbells oil, Wound healing, Wound contraction, Cream, Mice.

### Introduction

Wounds are eventually occurring due to physical, chemical or microbiological infections. Normal wound healing response begins immediately after the tissue is injured. Following injury, an inflammatory response occurs and the cells below the dermis start to increase synthesis of collagen and in later stages the epithelial tissue undergoes a significant regeneration.<sup>1</sup> The medicinal plant such as *Aleo vera* and *Calendula officinalis* are widely used in order to facilitate the healing process as well as shortening the three major stages of the healing process. However, the herbal therapy- because of lower costs and better results-obtained increasing interests.

Lint bells (*Linum usitatissimum*) is an herb belonging to the *Linaceae* family,<sup>2</sup> and is one of the oldest cultivated plants in the world which is cultivated for its fiber and oil.<sup>3</sup> Lint bells and its derivatives such as lintbells oil or lintbells are rich sources of the polyunsaturated fatty acids (PUFA) and essential fatty acids (EFA). For example the linoleic acid (omega-6 fatty acids), oleic acid, secoisolaricresinol diglucoside (SDG), flavonoids, phenolic acids, phenols, lignans and tannins are found in these plants.<sup>4, 5</sup>

In traditional medicine, Linum seed oil is used in heart disease,<sup>6</sup> some types of cancer,<sup>7, 8</sup> to control inflammation, for autoimmune disease,<sup>4</sup> and wound healing.<sup>9</sup> The therapeutic effects of different doses and pharmaceutical forms of linum seed oil have not been investigated. Therefore, the present study has been conducted to evaluate the effect of different therapeutic dosages and pharmaceutical forms (pure oil and medicated cream) on wound contraction and healing process.

Assistant professor, Department of Veterinary Surgery, Urmia Branch, Islamic Azad University, Urmia, Iran.  
Address all correspondence to Dr. Mohammad-Reza Farahpour (DVM, DVSc), E-mail: mrf78s@gmail.com

## Materials and Methods

### Experimental animals

60 healthy inbred Male Swiss albino mice of either sex (six males and six females in each group, weight: 25-30, age 7-8 weeks) were obtained from the animal house, veterinary colleges of Urmia University and used in the present study. All mice were housed in separate polyethylene cages for five days at standard experimental conditions of temperature ( $22 \pm 3^\circ\text{C}$ ), humidity ( $60 \pm 5$  %), and a 12h light/dark cycle for acclimatization. The animals were maintained on a standard pellet diet and tap water *ad lib*.

### Oil material and preparation of the topical creams

Pure linseed oil used in this study, purchased from the Barij Essence Company (Kashan, Iran), and transferred to the college of Veterinary Medicine, Azad University of Urmia, in a glass jar in a dark and closed with no contact with light and air. All the variants consisted base formulation comprising synthetic base cream (yellow soft paraffin; PARS DARUO. Ltd., Tehran, Iran).

Following wound induction, all mice randomly were labeled by none toxic color and divided into four groups of six animals each. Group A, negative control group (Untreated); Group B, vehicle animals, in which base formulation was administrated. Groups C and D, The experimental groups was treated with two doses of 2% and 4% from lintbells oil mixed with base formulation (LBOC 2% and 4%). Finally, in group E, surface of the wound was soaked with pure oil. In treatment groups, 0.4 gr of cream was applied topically on the wounded site, once a day, immediately from the day of operation until complete re-epithelialization. Daily observation was performed and any wound fluid or any evidence of infection or other abnormalities were noted.<sup>1</sup>

### Wound healing activity

#### Circular excisional wound model.

All mice weighed and anesthetized by intraperitoneal administration of a combination of the ketamine HCL 5% (70 mg/kg/IP; Alfasan International, Woerden, Holland) and Xylazine HCL 2% (5 mg/kg/IP; Alfasan International, Woerden, Holland). Then the mice were positioned and secured to surgical table in ventral recumbency position and the hair on the back of each animal was shaved and sterilized with 70% alcohol. Two circular, full thickness wounds, was created on each side of the thorax, on scapular region of each mouse, by excising the skin with 5 mm biopsy punch.

### Wound area measurement

The surface of the wound during experiment period was measured and reported in percentage. A transparency paper and a permanent marker were used in order to

measure and record the wound size at the 3, 6, 9, and 12 days after surgery.<sup>1,10</sup>

### Histopathological study

The full-thickness skin specimens were harvested on the 3<sup>rd</sup>, 6<sup>th</sup> and 12<sup>th</sup> days after surgery, following sacrificing the animals. Sample excised along with 1 to 2mm surrounding normal skin. The specimens were then fixed in 10% formalin. Following tissue processing, 5  $\mu\text{m}$  sections were prepared and stained with Masson's trichrome staining technique and studied under light microscope.

Three parallel sections were studied in each slide for the following parameters: Cellular infiltration (Mononuclear cells, polymorph nuclear cells and Fibroblastic distribution) and new vessels bud were qualitatively evaluated in five high power fields (HPFs) ( $\times 400$ ). Moreover, the blood congestion, edema, fibroplasia, collagen deposition and intensity, fibrin and scar were qualitatively evaluated as absent (-), mild (+), moderate (++) , severe (+++) and extensive (++++) ( $\times 100$ ).<sup>3,11</sup>

### Statistical Analysis

Experimental results were expressed as means  $\pm$  SD. Statistical analyses were performed using PASW 18.0 (SPSS Inc., Chicago, IL, USA). Model assumptions were evaluated by examining the residual plot. Results were analyzed using one way ANOVA. Dunnett's test for pair-wise comparisons was used to examine the effect of time and treatments. Differences were considered significant when  $P < 0.05$ .

## Results

### Wound contraction

Observations revealed that administrating the 2% and 4% from LBOC significantly increased wound contraction ratio versus those in non-treated animals ( $P < 0.05$ ) (Table 1).

### Histopathological evaluation

Histological analyses showed that the LBOC remarkably reduced the time of inflammatory stage, accordingly, the animals in LBOC-treated group manifested significantly lower immune cells infiltration, edema, blood congestion and rapid generation of granulation tissue. Moreover, the animals in treated group exhibited rapid proliferation of fibroblasts and shortened proliferative phase. Animals in LBOC-administrated group also revealed a significant enhancement in collagen deposition and maturation. However, the animals in 2% LBOC-treated group showed better results in comparison to those in 4%

group. In contrast, the animals in non-treated group showed higher immune cells infiltration (++++), remarkable edema (++++), and considerably higher congestion (++++), in inflammatory phase. Moreover, these animals presented lower fibroblast distribution

(++), neovascularization (++) as well as lower collagen deposition (++) comparing to those in treated groups. The data for histopathological analyses are presented in table 2.

**Table 1-** Histological evaluation of lint bells oil on wound healing processes in different groups of treatment in mice.

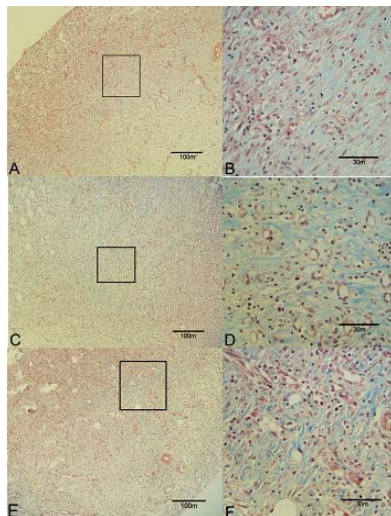
Days	Concentrations	U	Ed	PMN	MNC	NV	FP	CD
3	Vehicle	++++	++++	++++	+	+	-/+	-
	Negative control	++++	++++	++++	+	+ / + +	+	-
	LBOC 2%	+++	+++	+++	++ / + + +	++ / + + +	++	- / +
	LBOC 4%	+++	+++	+++	++	++	+ / + +	- / +
	Pure Lint bells oil	++++	++++	++++	++	+ / + +	+	-
6	Vehicle	+++	+++	++ / + + +	++ / + + +	++	++	+
	Negative control	+++	+++	++	+++	++	++ / + + +	+ / + +
	LBOC 2%	++	+ / + +	+ / + +	++++	+++	++++	++ / + + +
	LBOC 4%	++	++	++	+++	++	+++	++
	Pure Lint bells oil	+++	+++	++	+++	++	++ / + + +	+ / + +
12	Vehicle	+ / + +	- / +	+	++	+ / + +	+	++
	Negative control	+	+	+ / + +	+ / + +	+	++	++ / + + +
	LBOC 2%	- / +	- / +	- / +	+	+ / + +	+++	++++
	LBOC 4%	+	- / +	- / +	+	+	++	+++
	Pure Lint bells oil	+	+	+	+ / + +	+	++	++ / + + +

Hematoxylin and eosin stained sections were scored as absent (-), present (+), mild (++) , moderate (+++) and severe (++++), for Ed: Edema; U: Ulceration; NV: Neovascularization; PMNs: Polymorph nuclear cells; FP: Fibroblast proliferation; MNC: Mononuclear cells; CD: Collagen Deposit.

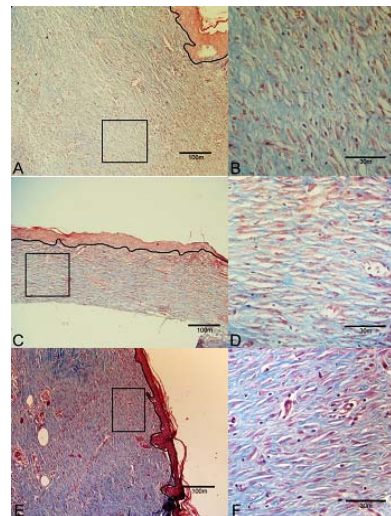
**Table 2-** Effect of lint bells oil (LBOC) on wound area

	Wound area (mm <sup>2</sup> ) ± SD.			
	Day 3	Day 6	Day 9	Day 12
Negative control	16.05 ± 3.21	12.34 ± 2.28	7.22 ± 2.19	3.50 ± 0.87
Vehicle	15.19 ± 3.11	11.25 ± 2.18	7.03 ± 1.98	3.19 ± 0.87
LBOC 2%	13.95 ± 0.23	5.54 ± 0.17 <sup>a</sup>	2.91 ± 0.27 <sup>a</sup>	0.78 ± 0.05 <sup>a</sup>
LBOC 4%	14.95 ± 0.28	6.81 ± 1.75	3.69 ± 0.13 <sup>b</sup>	1.01 ± 0.27 <sup>b</sup>
Pure Oil	15.45 ± 2.32	10.17 ± 3.27	6.24 ± 0.39	2.94 ± 0.22

Results are as standard error mean for 6 rats per group.  
\*P<0.05 and vs Control



**Figure 1-** Masson trichrom stained sections of granulation tissue in the control (A and C), LBOC 4% (C and D) and LBOC 2% (E and F) group at 6 day after wound creation.



**Figure 2-** Masson trichrom stained sections of granulation tissue in the control (A and C), LBOC 4% (C and D) and LBOC 2% (E and F) group at 12 days after wound creation.

Moreover, the histological assessments revealed that LBOC inhibited the wound-induced inflammatory phase and stimulated the proliferative phase by enhancing the fibroblasts distribution and/or proliferation. Ultimately, it promoted the healing process by facilitated the collagen synthesis, deposition and maturation. However, all stages of healing process delayed in non-treated animals significantly.

The wound healing process consists three overlapping phases such as; inflammation, granulation tissue formation and remodeling of the extra cellular matrix.<sup>12</sup> Different studies show that the intake of fatty acid, which found in soy, corn, sunflower, fish, Lintbells, and canola oils, have the ability to modify growth factor activity, cell differentiation, and cell proliferation.<sup>13,15</sup>

Lintbells (*Linum usitatissimum*) is an herb belonging to the *Linaceae* family,<sup>2</sup> and its derivatives lintbells oil or lintbells, are rich sources of the PUFA, EFA, fatty acids (alpha-linolenic acid and linoleic acid) and SDG as an anti-oxidant component.<sup>4,2</sup> According to previous studies the mentioned chemicals are known to be as essential agents in provoking the healing process.<sup>9,16</sup> Therefore, as a preliminary conclusion we can suggest that LBOC promoted the healing process because of high concentration of PUFA, EFA, omega 3, omega 6 and other mentioned agents.

Several studies emphasized that, antioxidants,<sup>11, 14</sup> and phenolic compounds<sup>17, 18</sup> exert a promoting impact on accelerating skin wound healing and are able to enhance wound contraction ratio. On the other hand, the SDG- as an antioxidant agent- significantly improves the healing process. In this regard, it is reported that there is a positive correlation between controlling the oxidative stress and shortening the healing process. Thus, it can be concluded that LBOC in 2% form of administration stimulated the healing process because of massive amount of SDG.

Histopathological analyses showed that 2% LBOC resulted in reducing immune cells infiltration and enhanced the fibroblasts proliferation. Fibroblasts are the main cells in synthesis of dermal matrix as well as collagen fibers, so, we can suggest that LBOC increased the collagen deposition via elevating the fibroblasts proliferation. Comparing the 2% and 4% LBOC showed that the 2% LBOC-treated animals exhibited better results. It can be attributed to its irritant impact in higher doses. As shown in table 2, 4% LBOC resulted in longer inflammatory stage in comparison to those in lower dose-treated group. On the other hand it is reported that

the antioxidant chemicals are able to reduce the inflammatory reactions in healing process.<sup>14, 18</sup>

Moreover, the angiogenesis and infiltration of macrophages in wound area play an essential role in the healing process via reducing the oxidative stress, nutrients delivery and promoting the structural cells (mast cells and fibroblasts) proliferation.<sup>12</sup> Our observations demonstrated that the angiogenesis increased in 2% LBOC-treated animals associated with increased fibroblasts distribution. Thus, LBOC induced angiogenesis, and ultimately provoked the proliferative phase, which is reported to other plants.<sup>11, 14</sup>

In fact, administering the oil formulation naturally allows the wound area to keep the optimal humidity which is necessary for better re-epithelialization.<sup>9, 19</sup> Our analyses showed that the animals in LBOC-treated group had much better re-epithelialization. Although the animals in pure oil-treated group showed improved re-epithelialization, those in LBOC-treated groups exhibited better results. Thus, it could be suggested that the only moisturizing of the wound area is not sufficient and/or appropriate enough to improve the healing process but the longer maintenance of the cream preparation over the wound, in comparison with the pure oil is important.

These results confirm the findings of other researchers on the effects of lint bells oil to reduce wound area, amount of inflammatory cells and edema, increase collagen deposition and accelerated wound healing process.<sup>9, 13</sup>

## Conclusion

According to our study, topical administration of 2% LBOC remarkably promoted the healing process. Moreover, we showed that the LBOC shortened the inflammatory stage and stimulated the proliferative phase, cellularity and ultimately improved the maturation phase by illustrating LBOC-induced collagen bundling and complete epithelialization.

## Acknowledgements

The author grateful to Aidin Dilmaghanian (PhD) for histopathological assessment.

## References

1. Farahpour M, Habibi M. Evaluation of the wound healing activity of an ethanolic extract of Ceylon cinnamon in mice. *Vet Med* 2012; 57: 53-57.
2. Diederichsen A, Richards K. Flax: the genus *Linum*. Edited by Alistair D, Muir and Neil D, Westcott CRC Press 2003;34.
3. Güvenç A, Küpeli Akkol E, Hürkul MM, et al. Wound healing and anti-inflammatory activities of the *Michauxia L'Hérit* (Campanulaceae) species native to Turkey. *J Ethnopharm* 2012;139: 401-408.

4. Žuk M, Kulma A, Dymińska L, et al. Flavonoid engineering of flax potentiate its biotechnological application. *BMC Biotechnol* 2011; 11: 10.
5. Sagar JK, Chen J, Corey P, et al. The effect of secoisolariciresinol diglucoside and flaxseed oil, alone and in combination, on MCF-7 tumor growth and signaling pathways. *Nutr Cancer* 2010; 62: 533-542.
6. Pan A, Yu D, Demark-Wahnefried W, Franco OH, et al. Meta-analysis of the effects of flaxseed interventions on blood lipids. *Am J Clin Nutr* 2009; 90: 288-297.
7. Chen J, Wang L, Thompson LU. Flaxseed and its components reduce metastasis after surgical excision of solid human breast tumor in nude mice. *Cancer Lett* 2006; 234:168-175.
8. Thompson LU, Chen JM, Li T, et al. Dietary flaxseed alters tumor biological markers in postmenopausal breast cancer. *Clin Cancer Res* 2005; 11: 3828-3835.
9. Franco EdS, de Aquino CMF, Medeiros PLd, et al. Effect of a Semisolid Formulation of Linum usitatissimum L.(Linseed) Oil on the Repair of Skin Wounds. *J Evid Based Compl Alt* 2011; 2012.
10. Mohammadpour M, Behjati M, Sadeghi A, et al. Wound healing by topical application of antioxidant iron chelators: kojic acid and deferiprone. *Int Wound J* 2013; 10: 260-264.
11. Süntar İ, Akkol EK, Şenol FS, et al. Investigating wound healing, tyrosinase inhibitory and antioxidant activities of the ethanol extracts of *Salvia cryptantha* and *Salvia cyanescens* using in vivo and in vitro experimental models. *J Ethnopharm* 2011; 135: 71-77.
12. Beldon P. Basic Science of wound healing. *Surgery (Oxford)* 2010; 28: 409-12.
13. De Spirt S, Stahl W, Tronnier H, et al. Intervention with flaxseed and borage oil supplements modulates skin condition in women. *Br J Nutr* 2009; 101: 440.
14. Nayak BS, Sandiford S, Maxwell A. Evaluation of the wound-healing activity of ethanolic extract of *Morinda citrifolia* L. leaf. *J Evid Based Compl Alt* 2009; 6: 351-356.
15. Otranto M, Do Nascimento AP, Monte-Alto-Costa A. Effects of supplementation with different edible oils on cutaneous wound healing. *Wound Rep Reg* 2010; 18: 629-636.
16. Datta HS, Mitra SK, Patwardhan B. Wound healing activity of topical application forms based on Ayurveda. *J Evid Based Compl Alt* 2011; 2011.
17. Fernandez SP, Nguyen M, Yow TT, et al. The flavonoid glycosides, myricitrin, gossypin and naringin exert anxiolytic action in mice. *Neurochem Res* 2009; 34: 1867-1875.
18. Sen CK, Khanna S, Gordillo G, et al. Oxygen, oxidants, and antioxidants in wound healing. *Ann NY Acad Sci* 2002; 957: 239-249.
19. Dyson M, Young S, Pendle CL, et al. Comparison of the effects of moist and dry conditions on dermal repair. *J Invest Dermatol* 1988; 91: 434-439.

## چکیده

### ارزیابی کاربرد موضعی روغن بزرک در دزهای مختلف بر التیام زخم برشی دایره شکل در مدل تجربی

محمد رضا فرهپور

گروه علوم بالینی، دانشکده دامپزشکی، واحد ارومیه، دانشگاه آزاد اسلامی، ارومیه، ایران.

**هدف-** هدف بررسی اثر کاربرد موضعی روغن بزرک بر روی میزان انقباض زخم و تغییرات آسیب شناختی

**طرح-** مطالعه تجربی

**حیوانات-** ۶۰ سر موش نر نژاد سوئیس

**روش کار-** ۶۰ سر موش نر نژاد سوئیس به ۵ گروه ۱۲ موش تقسیم شدند (گروه شاهد، دارونما و گروه‌های درمانی در سه دوز کرم ۲، کرم ۴٪ و گروه دریافت کننده روغن خالص). دو زخم دایره شکل، تمام ضخامت در هر دو طرف ستون فقرات، ۱ سانتی‌متر به دور از ستون فقرات و فاصله ۲ سانتی‌متری از یکدیگر توسط پانچ بیوپسی ۵ میلی‌متر در شرایط استریل ایجاد گردید. درصد انقباض زخم در روزهای ۳، ۶، ۹ و ۱۲ بعد از عمل جراحی، با کاغذ شفاف اندازه‌گیری شدند. نمونه‌های بافتی در پایان روزهای ۳، ۶ و ۱۲ از تمام گروه‌ها تهیه گردیده و با رنگ تری کروم ماسون مورد رنگ‌آمیزی و در زیر میکروسکوپ نوری مورد بررسی قرار گرفتند.

**نتایج-** کاهش سطح زخم در گروه تحت درمان با کرم حاوی روغن بزرک، اثر قابل توجهی را نشان داد. همچنین مطالعه بافت شناسی نشان داد در گروه‌های درمانی، به خصوص فرمولاسیون دوز پایین کرم روغن بزرک (LBOC 2٪)، تعداد سلول التهابی کمتر، رسوب کلاژن و دوباره‌سازی بافت پوششی بیشتر نسبت به سایر گروه‌ها، و بخصوص گروه شاهد وجود دارد.

**نتیجه‌گیری-** داده‌های تجربی نشان داد که فرمولاسیون‌های دارویی کرم روغن بزرک ۲٪، اثر قابل توجهی بر روند التیام زخم غیر عفونی را نشان می‌دهد.

**کلمات کلیدی-** روغن بزرک، التیام زخم، انقباض زخم، کرم، موش کوچک آزمایشگاهی