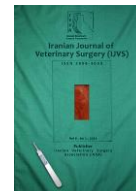



Iranian Veterinary Surgery Association

IRANIAN JOURNAL OF VETERINARY SURGERY

Journal homepage: www.ivsajournals.com

ORIGINAL ARTICLE

Investigating the Echocardiography and Heart Anatomy of Immature Beluga (*Huso huso*) With the Aim of Providing Standard Approaches

Omid Zehtabvar¹, Ali Reza Vajhi^{2*}, Zahra Tootian¹, Majid Masoudifard², Somaye Davudypoor²

¹ Anatomy sector, Department of Basic science, Faculty of Veterinary Medicine, University of Tehran, Tehran, Iran.

² Department of Surgery and Radiology, Faculty of Veterinary Medicine, University of Tehran, Tehran, Iran.

Received: 23 September 2018

Accepted: 6 February 2019

Available Online: 17 March 2019

Keywords:

Immature beluga (*Huso huso*);
Heart;
Anatomy;
Echocardiography.

Abstract

Objective- The purpose of present study was to obtain a complete understanding about anatomical features and echocardiography of beluga (*Huso huso*) species in order to provide standard approaches for performing echocardiography on this sturgeon species.

Design- Experimental study.

Animals- 10 immature (2.5 years old) beluga (*Huso huso*).

Procedures- To perform echocardiography, Sonosite-MicroMaxx ultrasonography machine and linear probe with a frequency of 6-12 MHz of ventral approach between two pectoral fins were used.

Results- Four main parts of the heart were identified in investigations and the way of locating and connections of these parts were examined. Sinus venosus had a thin wall and leaned toward left. The atrium wall was characterized by connective tissue and muscle. There was a valve structure between sinus venosus and atrium. The ventricle had a thick muscular wall with a two-layer appearance. Conus arteriosus leaned toward right. This part had three rows of valves including one distal row and two proximal rows with a certain distance between the distal row and the two proximal rows.

Conclusion and Clinical Relevance- Since there has not yet been a complete study on the heart of beluga species in the terms of ultrasonography and anatomy, the present study can be utilized as a basis for investigating other sturgeon species. In the present study, a standard approach has been provided to perform echocardiography on beluga species.

* Correspondence to: Ali Reza Vajhi, Department of Surgery and Radiology, Faculty of Veterinary Medicine, University of Tehran, Tehran, Iran.

E-mail: avajhi@ut.ac.ir

1. Introduction

The structural and functional differences of circulatory system in vertebrates are closely related to their life style. A number of these differences are related to the ability of circulatory system to exchange gases under different atmospheric pressures.^{9,10} One of the most important differences between aquatic and terrestrial organisms is the difference between their heart and vessels.^{4,5,13} Fishes are one of the vertebrate species. The many diverse physiological needs of fishes have led to a variety of life styles due to their very diverse environmental conditions.⁷ As an example, the circulatory system of Scombroidei group has important taxonomic characteristics. Similarly, the branching pattern of arteries in Elasmobranch group is very important and their investigation can lead to achieve phylogenetic hypotheses.¹³ Sturgeon species is one of the most important aquatic species in Iran.¹⁶ Better understanding about anatomical features of circulatory system in these fishes can be significantly helpful in conducting various further researches and consequently, preserving these endangered species.

Echocardiography as one of the best methods for investigating the heart of living creatures can be also used to more detailed investigation of this sturgeon species' heart.² Understanding the anatomy of circulatory system and how to perform echocardiography and its features in sturgeon species means to utilize from anatomy knowledge to conduct various studies on the circulatory system. Echocardiography has ever been performed on some fish such as Zebrafish and several species of sharks.¹⁴ Chin Lai *et al* (2004) utilized from echocardiography to comprise cardiac ventricular function in five species of shark.¹¹ Gregory *et al* (2004) performed echocardiography on *Acipenser transmontanus* species to investigate the relationship of pericardium and pericardioperitoneal canal (PPC) with cardiac function.³ The anatomical structure and developmental stages of this structure in some sturgeon species have been also studied by other scientists. Icardo *et al* (2009) investigated the developmental stages of the heart structure in *Acipenser naccarii* species.⁶ Icardo *et al* (2002) considered the histology of conus arteriosus in *Acipenser naccarii* species.^{4,5} Also, the researchers used ultrasonography to determine the sex of sturgeon species.¹² Zehtabvar *et al* (2018) conducted a study on tissue structure and echocardiography presentation of various parts of the heart in beluga (*Huso huso*).¹⁶

Since one of the most important species of sturgeon in Iran and in the world is beluga (*Huso huso*),¹⁶ this species was selected to conduct present study. The purpose of present

study was to obtain a complete understanding about anatomical features and echocardiography of beluga (*Huso huso*) species in order to provide standard approaches for performing echocardiography on this sturgeon species.

2. Materials and Methods

Samples

A number of 10 immature beluga (*Huso huso*) with a mean weight of 3.5 ± 0.5 kg and an approximate age of 2.5 years were purchased from a private culturing center located in Mohammad Shahr of Karaj and lively transferred to faculty of veterinary medicine, University of Tehran using plastic barrels. It should be noted that the species were examined through ultrasonography based on the standard method provided in references¹⁵ before purchasing and all male samples were selected. After transferring samples to faculty of veterinary medicine, they were kept in special plastic cylindrical containers at the aquarium for 24 hours to return to their natural physiological conditions.

Echocardiographic study

Sonosite-MicroMaxx ultrasonography machine and linear probe with a frequency of 6-12 MHz were used to perform echocardiography. In a rectangular plastic tub filled with water, each sample was held with hand so that its ventral surface was upward. Since the topographic area of the heart in sturgeons is between Pectoral Fins, the probe was placed in this area (ventral approach) to perform echocardiography.

In longitudinal state, the probe was moved toward left and right sides through Sliding movement for more detailed investigations. For further investigation of anterior parts, the probe was also moved toward anterior direction in both longitudinal and transverse states. In addition, Doppler system was used to investigate blood flow. To examine different parts of the heart and corresponding parts, the probe was moved toward posterior, anterior, right and left in above mentioned positions through sliding and fanning movements. It should be noted that anesthesia was not used for samples due to the lack of their resistance in echocardiography stage.

In present study, a hypothetical triangle was considered to explain the location of placing probe for echocardiography so that this hypothetical triangle was created in ventral surface between the pectoral fins and two hard cartilage structures, which represented the topographic position of pericardial cavity (Figure 1).

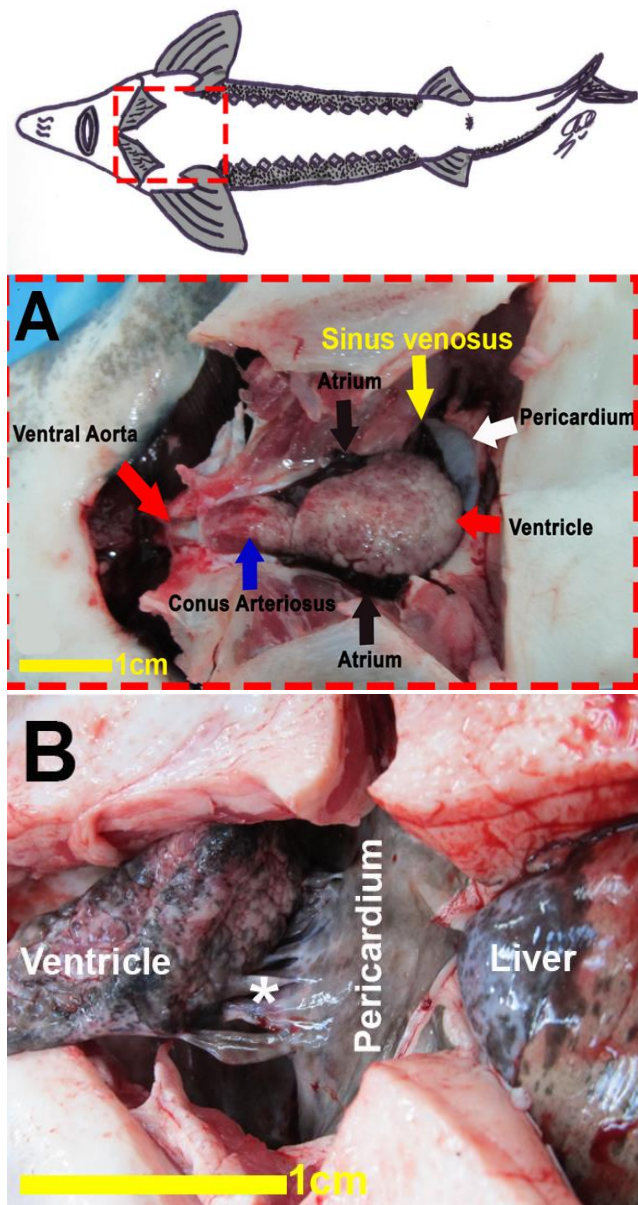


Figure 1. A: a ventral view for pericardial cavity location of immature beluga and its structures; the range of image A has been shown in the left schematic illustration; B: more zoom-in of posterior part of the heart, pericardium and liver, the connections between ventricle and pericardium have been shown with a star.

Anatomical study

After echocardiography and data recording, the samples were removed from water and anatomical examinations were carried out immediately after samples' death. The skin and wall of the body between pectoral fins were removed through three incisions in this part and the pericardial cavity became available to conduct investigations. Images were provided using Olympus SZX12 Loop equipped with ASP-CellPad E digital camera.

3. Results

Echocardiography study

All structures of the heart including sinus venosus, atrium, ventricle, conus arteriosus and pericardium were visible through longitudinally placing the probe between pectoral fins (Figures 2,4). As it can be seen from echocardiograms, sinus venosus and atrium were placed higher compared with two other structures. Atrium was more anterior compared with sinus venosus. Ventricle and conus arteriosus were placed lower compared with two other structures. Conus arteriosus was more anterior compared with ventricle (Figure 2). During taking transverse echocardiograms, ventricle and sinus venosus were observable in echocardiogram; when the probe was located in the most posterior area of hypothetical triangle (near the base of triangle). Atrium, ventricle and conus arteriosus were observed in central areas of hypothetical triangle, when the probe was moved to toward anterior position (towards the vertex of triangle). Conus arteriosus and atrium were observed in more anterior areas close to vertex of hypothetical triangle, the conus arteriosus was only observed (Figure 3). In transverse echocardiograms, sinus venosus was the most posterior structure of the heart and slightly tilted toward left. The sinus venosus was evacuated to atrium on the midline of the body and atrium was also evacuated to ventricle from left side. Ventricle and atrium placed on the midline of the body. Ventricle was evacuated to conus arteriosus from right side. The conus arteriosus was initially slightly tilted toward right side but in continue, placed on the midline of body. When imaging was made in the form of Right Parasagittal, all four cardiac cavities as well as the connection between ventricle and conus arteriosus were observable (Figure 6). When echocardiogram was prepared median, some parts of all four cardiac cavities were again observable; but the connection between ventricle and conus arteriosus was not observable (Figure 4).

In echocardiography, the blood flow was from sinus venosus to atrium, from there to ventricle and then to conus arteriosus. An interesting point observed in the circulatory system was that particles forming the blood were characterized as particles of echoic foci.

In continue the structure of heart's components has been investigated in echocardiography viewpoint. Pericardium was crocheted around the structures of the heart with a homogenous echogenicity. It was thicker on the posterior side i.e. near the ventricle and sinus venosus. The sinus venosus had a very thin wall with a non-muscular structure

and accordingly, had no contraction and expansion. This wall had a completely echogenic structure. A common structure formed by joining of two vessels that cross the liver was evacuated on midline inside the sinus venosus. The sinus venosus and ventricle as two parts of the heart were connected to posterior area of pericardium that formed the thick structure. A valve was observed at the point of sinus venosus evacuation to atrium, which opened and closed in a coordinated manner with the contraction and expansion of the atrium. The atrium had a completely muscular wall with contraction and expansion movement and had a greater size compared to sinus venosus. A valve was observed at the point of atrium evacuation to ventricle (Figure 2). The ventricle had a muscular wall. The wall had an external compact layer and an inner spongy layer. During investigating this structure with Doppler system, it was found that the blood is spread within spongy layer of ventricle when blood flow enters into ventricle (Figure 5). Conus arteriosus had a distinct muscular wall. Conus arteriosus had a tubular structure located between ventricle and ventral aorta. There were three rows of valves inside the conus arteriosus. Among them, two rows were close to each other and at the beginning of the cone and one row of valves placed at the end of the cone. There was a significant distance between the first two rows and the third row. In fact, the two first rows were posterior and the third row was anterior (Figure 2).

Anatomical study

Pericardial cavity was approximately isolated from peritoneal cavity and was cranioventral relative to it. Different parts of the heart were located in triangular pericardial cavity. The vertex of this triangle was on anterior side and its base was on posterior side. This cavity was surrounded by pericardium. In the posterior part (base of hypothetical triangle) the pericardium was thicker than the other parts and created a diaphragm like structure that separated the cavity from peritoneal cavity. The pericardium and pericardial cavity continued from anterior to the beginning of Ventral aorta (vertex of triangle). The two vessels that connected to heart formed a common structure which crossed within the posterior part of pericardium to reach the venous sinus. Some connections were observed between posterior part of ventricle and pericardium (Figure 1).

Atrium and sinus venosus were situated in a dorsal position and conus arteriosus was located in a ventral position. Sinus venosus and ventricle were situated in a more caudal position compared with two other structures. Atrium and conus arteriosus were also located in a more cranial

position compared with the two other structures (Figure 7). The atrium extends slightly from anterior part to the conus arteriosus and adjoins it (Figure 1). The sinus venosus entered to atrium on the midline of the body, the atrium entered to ventricle from left side, and ventricle entered to conus arteriosus from right side.

The sinus venosus had a very thin wall and can be investigated as long as the heart being active. But after stopping the heart and pulling out, it cannot be investigated. A valve was observed between the sinus venosus and the atrium. The atrium had a muscular wall, which seemed one-layer in a macroscopically appearance. There was a valve between atrium and ventricle. The ventricle had a thick muscular wall, which seemed two-layer in a macroscopically appearance. Its external layer was dense and connected to pericardium and its internal layer was spongy and had connection with the blood entered to ventricle. Conus arteriosus had a tubular appearance, which its beginning part had a larger diameter and its end part had a smaller diameter. Conus arteriosus had a wall with distinct muscle. At the beginning of cone, there were two rows of valves, which placed close to each other and there was also a row of valves at its end part. The ventral aorta was expanded after this structure.

4. Discussion

According to the observations of the present study it can be said that the pericardial cavity in beluga is a triangular cavity surrounded by pericardium, which the structures of the heart are located inside it. This cavity is located in a cranioventral position in relation to coelomic cavity. The pericardial cavity in its ventral part is situated adjacent to the ventral wall of body. It is also adjacent to esophagus from dorsal part and adjacent to the structures of pectoral fins from lateral part. The pericardium is thicker on the posterior side adjacent to ventricular cavity, which creates diaphragm like structure. In available references, such a structure has been also mentioned for sturgeon and shark species and the posterior part of pericardium is called transverse septum.^{7,8,16} The thick structure of this part creates a more elastic state of heart contraction, which provides a good opportunity to fill the blood of veins.⁸ In bony fishes, the pericardial cavity is a part of coelomic cavity that is isolated from other parts by pericardium. In contrast, this structure is isolated from ventricular cavity in sturgeon species.^{7,15} Gregory has referred to the presence of a canal between pericardial cavity and ventricular cavity in *Acipenser transmontanus*, which is important for regulating pressure of the pericardial cavity. This canal is called the pericardioperitoneal canal (PPC).³ In this study,

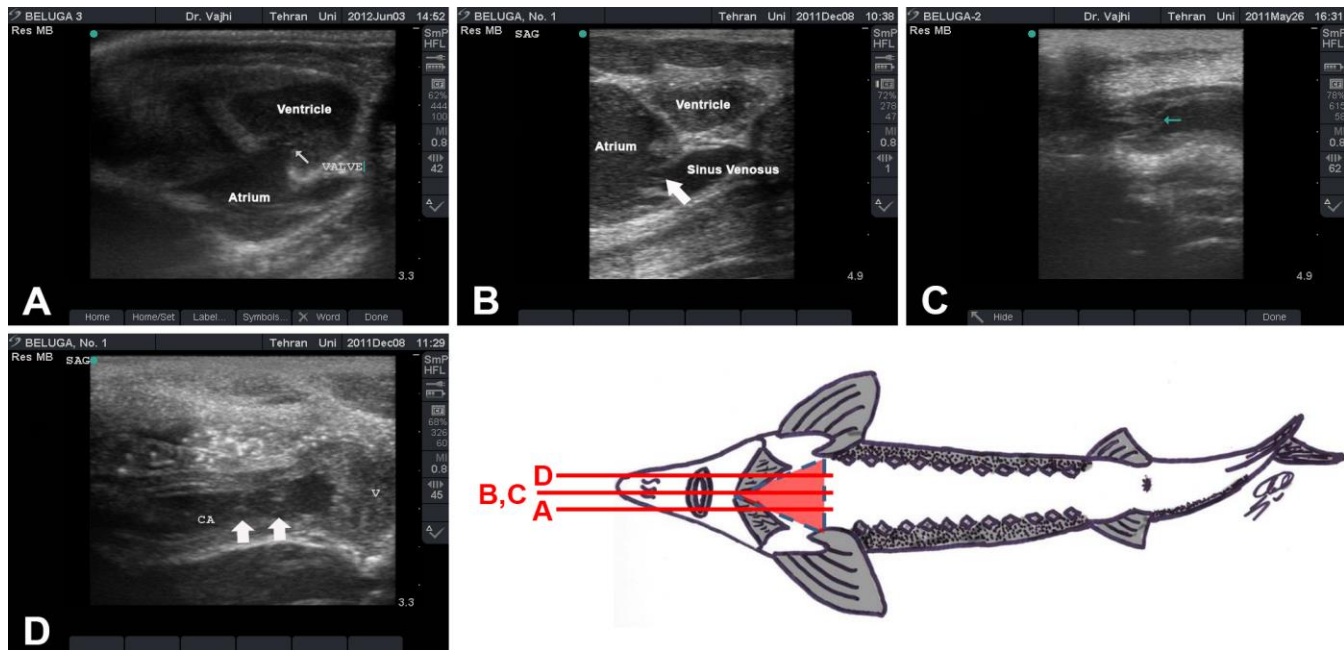


Figure 2. Longitudinal (long axis) echocardiograms from different structures of immature beluga's heart (A, B, C, and D); the echocardiogram section has been displayed in schematic illustration; the valve between atrium and ventricle has been shown in image A using arrow; the valve between Atrium and Sinus venosus has been shown in image B using arrow; the end valve of conus arteriosus has been shown in image C using arrow; the first two rows of valves conus arteriosus have been shown in image D using arrow, which are located close to each other. (CA: conus arteriosus, V: ventricle).

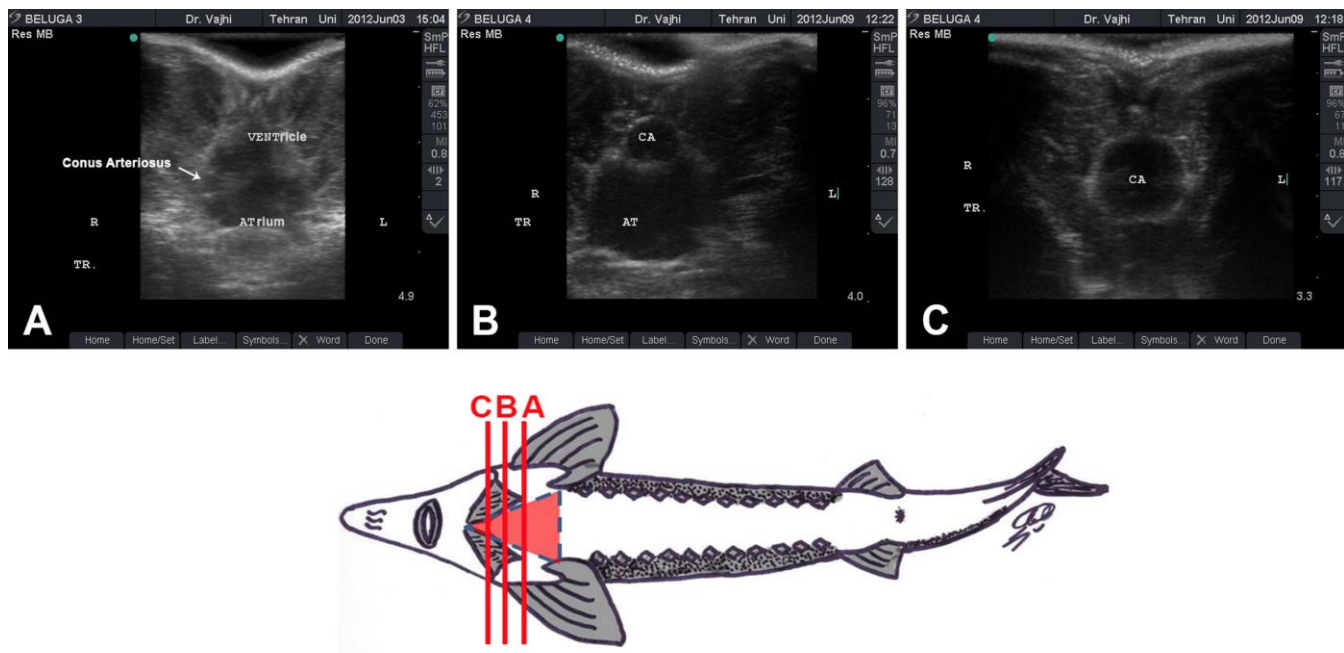


Figure 3. Transverse (short axis) echocardiograms from different structures of immature beluga's heart (A, B and C): the echocardiogram section has been displayed in schematic illustration. (CA: conus arteriosus, AT: atrium).

some connections were observed between posterior part of ventricle and pericardium, which can be related to PPC structure.

The heart of beluga consists of 4 main parts including sinus venosus, atrium, ventricle and conus arteriosus, which are

placed inside the pericardial cavity. The blood enters atrium after entering the venosus sinus, then moves toward ventricle and then enters the conus arteriosus. Conus arteriosus is the last part of heart and enters the blood to abdominal aorta which moves toward gills. The positioning

of these parts is so that they are located on sinus venosus in a caudodorsal form from posterior to anterior and then are located on the median line of the body from transverse septum. Zehtabvar *et al* (2018) in their study on tissue structure of sinus venosus have stated that this structure often consists of connective tissue and a small amount of muscle fibers.¹⁶ In the present study, sinus venosus was also mentioned as a thin wall without contraction and echogen.

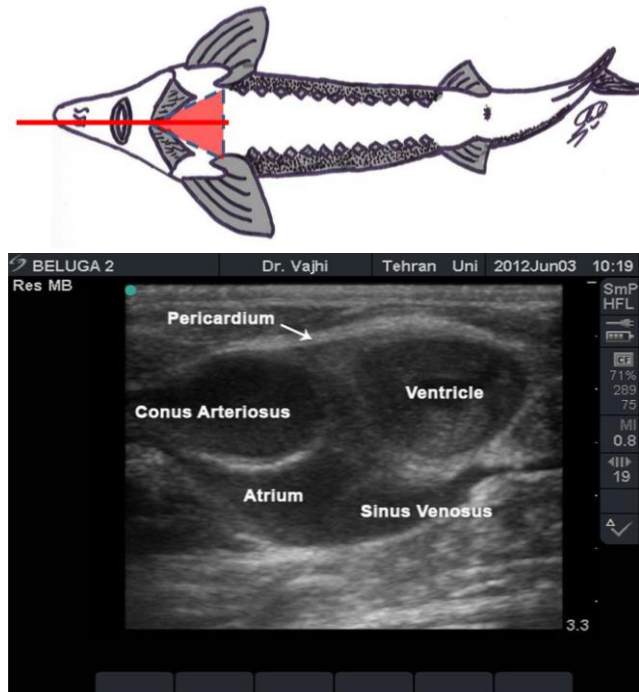


Figure 4. Median echocardiogram (long axis) from different structures of immature beluga's heart; the echocardiogram section has been displayed in schematic illustration.

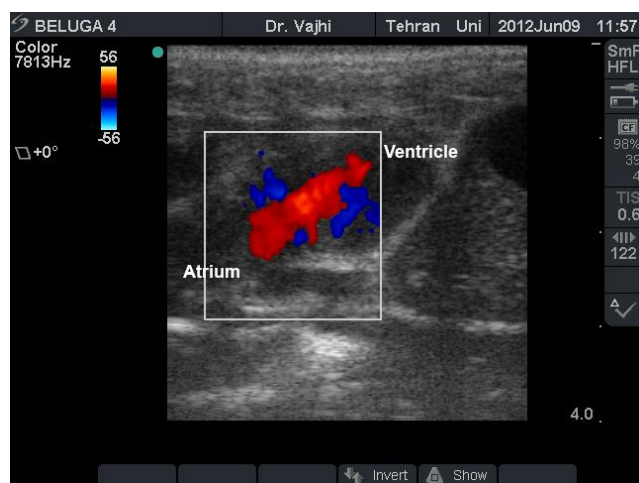


Figure 5. Color Doppler longitudinal (long axis) echocardiogram from Atrium and ventricle of immature beluga; entrance of blood from atrium to ventricle and within spongy muscles of the wall can be observed.

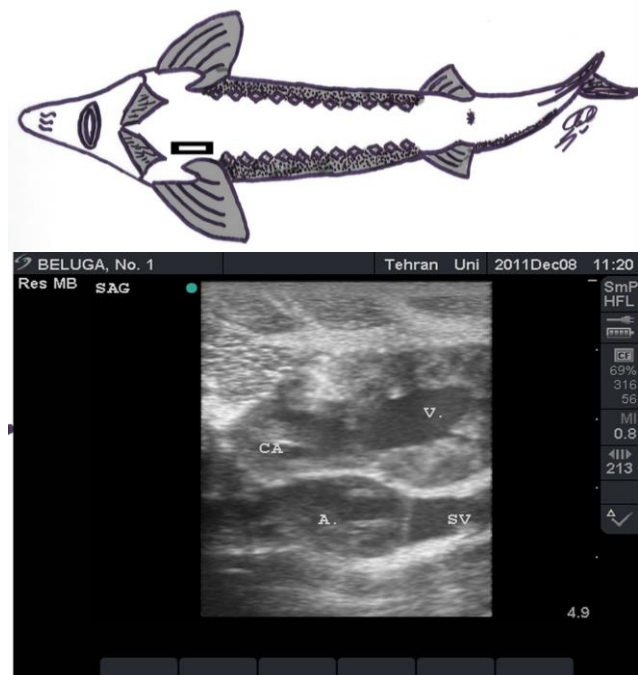


Figure 6. Right parasagittal echocardiogram of immature beluga; all four cavities of the heart are observable in this echocardiogram; the place of locating probe for preparation of right parasagittal echocardiogram has been shown in schematic illustration with a hollow rectangle. (CA: conus arteriosus, V: ventricle, A: atrium, SV: sinus venosus)

The entrance of sinus venosus to atrium was located in the mid line of the body and there was a valve between these two structures, which clearly characterized in echocardiography. This valve can be called sinoatrial valve. After the sinus venosus, atrium was located in a cranial form, which had dorsal position relative to the ventricle and conus arteriosus. The atrium had a very large volume when it was full of blood. Zehtabvar *et al* (2018) in their study on tissue structure of atrium have stated that atrium has a thicker wall than venous sinus and its muscle fibers are scattered in all directions.¹⁶ In the present study, atrium was also mentioned as a completely muscular wall with contraction and expansion.

On the left side of mid line, atrium is evacuated to the ventricle. Therefore, it was necessary to move the probe toward left side in order to observe this part in echocardiography. There is a valve between atrium and ventricle. The valve was observable in echocardiography at the evacuation point of atrium to ventricle, when the probe was moved toward left side. This valve can be called atrioventricular. In references, it has been noted that atrium causes flow and increase blood velocity by its contraction and expansion.¹⁶ The ventricle is located in ventral side of sinus venosus and atrium. At the time of blood flow to ventricle, the blood enters within the space of spongy

muscle layer, which can be seen in imaging using Doppler system and even by B mode ultrasonography. Zehtabvar *et al* (2018) in their study on the histology of beluga heart have stated that ventricle wall has a thick muscular structure.¹⁶ These muscles are completely distinguishable in two layers. One layer is compact and another in the internal part has a spongy form. Additionally, there are many erythrocytes that can be seen in the muscle fibers of spongy layer. In the present study, two muscular parts of ventricle wall and the entrance of blood within spongy layer were observable.

The entrance of ventricle to conus arteriosus is tilted toward right side of the mid line and it is necessary to

move the probe toward right side in order to observe this part in echocardiography. It has been noted that ventricle also increases the velocity of blood flow through its own pulse.⁸ The conus arteriosus is initially tilted toward right side and gradually lies on the mid line of the body (in anterior motion). Zehtabvar *et al* (2018) have mentioned that at least two muscular layers are observable in the arterial wall and the epicardium layer of conus arteriosus is merged with the pericardium.¹⁶ In the present study, the muscle structure of conus arteriosus was also observed.

Conus arteriosus is located in the anterior ventricle and continues along forehead. The atrium is also adjacent to conus arteriosus from above. Therefore, in transverse echocardiography, adjoining points of these two structures are observable. When the probe is moved toward posterior, a part of the ventricle that leaning toward left is added to this set and when the probe is moved toward anterior, the atrium gradually cannot be observed and one would find somewhere in the pericardial cavity that is located only in conus arteriosus. In their study, Icardo *et al* (2009) have stated that conus arteriosus has no effect on the blood velocity; rather it is a flexible cavity that reduces blood pressure fluctuations and turns the alternating flow of blood from the ventricle into a non-fluctuating and continuous flow.^{5,6} In addition, the conus arteriosus of beluga (*Huso huso*) has an oval shape. The structure has been also referred for *Acipenser naccarii*.^{4,5} There are three rows of valves inside the conus arteriosus. The first two rows are located close to each other and the third row is located far from these two before abdominal aorta. These structures are well characterized in echocardiography. According to the studies of Icardo *et al* (2002) these structures exist in a same way for *Acipenser naccarii* species. The first two rows of valves can be called “proximal conus valves” and the end row can be called the “distal conus valves”. First row between ventricle and conus arteriosus can be called “caudal proximal conus” or “Semilunar valves” and the second row is located later that can be called “cranial proximal conus valves”.^{4,5} About histological structure of the heart’s inner valves, Zehtabvar *et al* (2018) have stated that these valves are located on a border between structures in the form of connective tissue and covered by endocardial layer.¹⁶

According to the observations of the present study, it can be said that the probe should be placed longitudinally and transversely in the hypothetical triangle in order to provide images from different parts of the heart and the probe should be also moved toward left and right sides for further investigations. The places of locating probe and related movements for investigating different parts of beluga’s heart have been represented in Table 1.

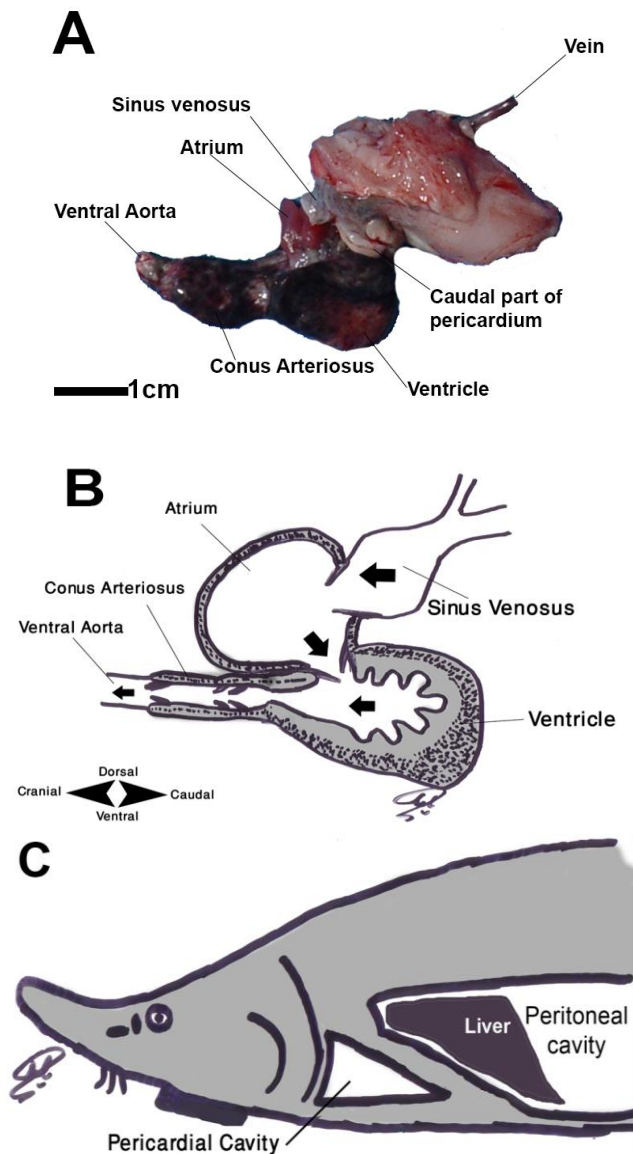


Figure 7. (A): a lateral view from heart sample of immature beluga; (B), a schematic illustration from internal structure of the heart, in this image, the path of blood flow has been displayed with arrows, (C): a schematic illustration from pericardial cavity and peritoneal cavity of immature beluga.

Table 1. The places of locating probe and related movements for investigating different parts of the heart in echocardiography of beluga.

The place of locating probe in hypothetical triangle	Imaging direction	Observable structures	Descriptions
The most posterior area (near the base of triangle)	Transverse	Ventricle, sinus venosus	-
Central areas	Transverse	Atrium, ventricle, conus arteriosus	By moving the probe toward anterior area relative to the previous stage
The more anterior parts of center	Transverse	Atrium, conus arteriosus	By moving the probe toward anterior area relative to the previous stage
Anterior areas (near the vertex of triangle)	Transverse	Conus arteriosus	By moving the probe toward anterior area relative to the previous stage
Central areas	Right parasagittal	Atrium, ventricle, conus arteriosus, sinus venosus and connection between ventricle and conus arteriosus	-
Central areas	Median	Atrium, ventricle, conus arteriosus, sinus venosus and connection between atrium and sinus venosus	-
Central areas	Left parasagittal	Sinus venosus, atrium, ventricle and connection between atrium and ventricle	-

Conflict of interest

None declared.

References

- Farrell AP. Cardiovascular systems in primitive fishes, *Fish Physiology*, 2007; 26:53-120.
- Goddard PJ. Veterinary ultrasonography. CABI, London, UK, 1st edition, 1995; 289-302.
- Gregory JA, Graham JB, Cech JJ, Dalton N, Michaels J, Lai NC. Pericardial and pericardioperitoneal canal relationships to cardiac function in the white sturgeon (*Acipenser transmontanus*). *Comparative Biochemistry and Physiology*, 2004, 138:203-213.
- Icardo JM, Colvee E, Cerra MC, Cerra MC, Tota B. the structure of the conus arteriosus of the sturgeon (*Acipenser naccarii*) heart. I: The conus valves and the subendocardium. *Anatomical Record*, 2002; 267:17-27.
- Icardo JM, Colvee E, Cerra MC, Tota B. The structure of the conus arteriosus of the sturgeon (*Acipenser naccarii*) heart: II. The myocardium, the subepicardium, and the conus-aorta transition. *Anatomical Record*, 2002; 268:388-398.
- Icardo JM, Guerrero A, Duran AC, Colvee E, Domezain A, Sans-Coma V. The developmental anatomy of the heart of the sturgeon *Acipenser naccarii*. Biology, conservation and sustainable development of sturgeons. Springer Science, 1st edition, Bern, Switzerland, 2009; 137-152.
- Iuliis GD, Pulera D. The Dissection of vertebrates, Academic Press, 2nd edition, Ontario, Canada, 2011; 27-79.
- Kapoor BG, Khanna B. Ichthyology handbook. Springer Science, 1st edition, Berlin, Germany, 2004; 249-308.
- Kardong, K. Vertebrates: Comparative anatomy, function, evolution. McGraw-Hill Education, 6th edition, New York, USA, 1998; 287-656.
- King, GM. Custance DRN. Colour atlas of vertebrate anatomy. Ferdowsi University press, 1st edition, Mashad, Iran, 1994; 33-42.
- Lai NC, Dalton N, Lai YY, Kwong C, Rasmussen R, Holts DB, Graham J. A comparative echocardiographic assessment of ventricular function in five species of sharks. *Comparative Biochemistry and Physiology*, 2004; 137:505-521.
- Moghim M, Vajhi AR, Veshkini A, Masoudifard M. Determination of sex and maturity in acipenser stellatus by using ultrasonography. *Journal of Applied Ichthyology*, 2002; 18(4-6):325-328.
- Muñoz-Chápuli R, Pérez-Pomares JM, Macías D, García-Garrido L, Carmona R, González-Iriarte M. The epicardium as a source of mesenchyme for the developing heart, *Italian Journal of Anatomy*

- and Embryology*, 2001; 106:187-96.
14. Sun L, Lien CL, Xu X, Shung KK. In vivo cardiac imaging of adult zebrafish using high frequency ultrasound (45-75 MHz), *Ultrasound in Medicine and Biology*, 2008; 34:31-39
 15. Vajhi AR, Masoudifard M, Moghim M, Veshkini A, Zehtabvar O. Ultrasonography of the sturgeons for sex and maturity determination, University of Tehran press, Tehran, Iran, 2011; 39-58.
 16. Zehtabvar O, Vajhi AR, Tootian Z, Masoudifard M, Sadeghinezhad J, Davudypoor S. Echocardiography and histology evaluation of the heart in the immature (2.5 years old) beluga, *Journal of Veterinary Research*, 2018; 72(4):467-473.

نشریه جراحی دامپزشکی ایران
سال ۲۰۱۹، جلد ۱۴ (شماره ۱)، شماره پیاپی ۳۰

چکیده

مطالعه اکوکاردیوگرافی و آناتومی قلب فیل ماهی (*Huso huso*) نابالغ با هدف ارائه رهیافت‌های استاندارد

امید زهتابور^۱، علیرضا وجهی^۲، زهرا طوطیان^۱، مجید مسعودی فرد^۲، سمیه داودی پور^۲

^۱ بخش آناتومی گروه علوم پایه دانشکده دامپزشکی دانشگاه تهران، تهران، ایران

^۲ گروه جراحی و رادیولوژی دانشکده دامپزشکی دانشگاه تهران، تهران، ایران

هدف: این مطالعه جهت به دست آوردن شناختی کامل از ویژگی‌های آناتومی و اکوکاردیوگرافی قلب فیل ماهی و ارائه رهیافت‌های استاندارد برای انجام اکوکاردیوگرافی در این ماهی انجام شد.

طرح مطالعه: مطالعه تجربی

حیوانات: ۱۰ عدد فیل ماهی نابالغ ۲/۵ ساله

روش کار: برای انجام اکوکاردیوگرافی از دستگاه Sonosite – MicroMaxx و پرآب خطی، با فرکانس ۶ – ۱۲ مگاهرتز از رهیافت سطح زیرین بدن بین دو باله سینه‌ای به صورت طولی و عرضی استفاده شد.

نتایج: در بررسی‌های انجام شده چهار بخش اصلی قلب مشخص شد، شیوه قرارگیری و ارتباط این بخش‌ها مورد بررسی قرار گرفت. سینوس سیاهرگی دارای دیواره‌ای نازک بود و متمایل به سمت چپ قرار داشت. دیواره دهلیز با بافت همبندی و عضله مشخص بود. بین سینوس سیاهرگی و دهلیز ساختاری دریچه‌ای مشخص بود. بطن دارای دیواره عضلانی ضخیمی بود که ظاهری دولایه‌ای داشت. مخروط سرخرگی متمایل به راست قرار داشت، این بخش دارای سه ردیف دریچه بود، یک ردیف دیستال و دو ردیف پروگزیمال که بین این ردیف دیستال و ردیف‌های پروگزیمال فاصله مشخصی بود.

نتیجه‌گیری و کاربرد بالینی: از آنجایی که تا به حال بررسی کاملی چه از نظر سونوگرافی و چه از نظر آناتومی روی قلب فیل ماهی انجام نشده است، این بررسی می‌تواند به عنوان مطالعه‌ای پایه‌ای برای سایر ماهیان خاویاری مورد استفاده قرار گیرد. در این مطالعه روش استاندارد برای انجام اکوکاردیوگرافی در فیل ماهی ارائه شد.

واژه‌های کلیدی: فیل ماهی نابالغ، قلب، آناتومی، اکوکاردیوگرافی